

# CASE OF THE WEEK

## PROFESSOR YASSER METWALLY

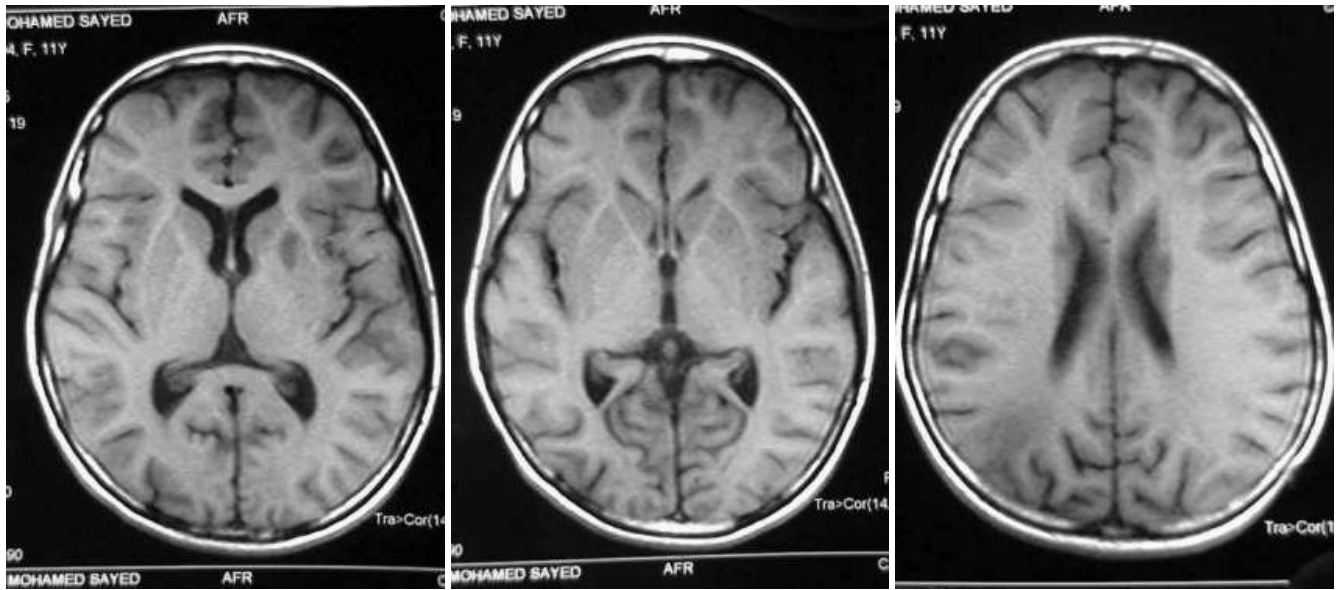
### CLINICAL PICTURE

#### CLINICAL PICTURE

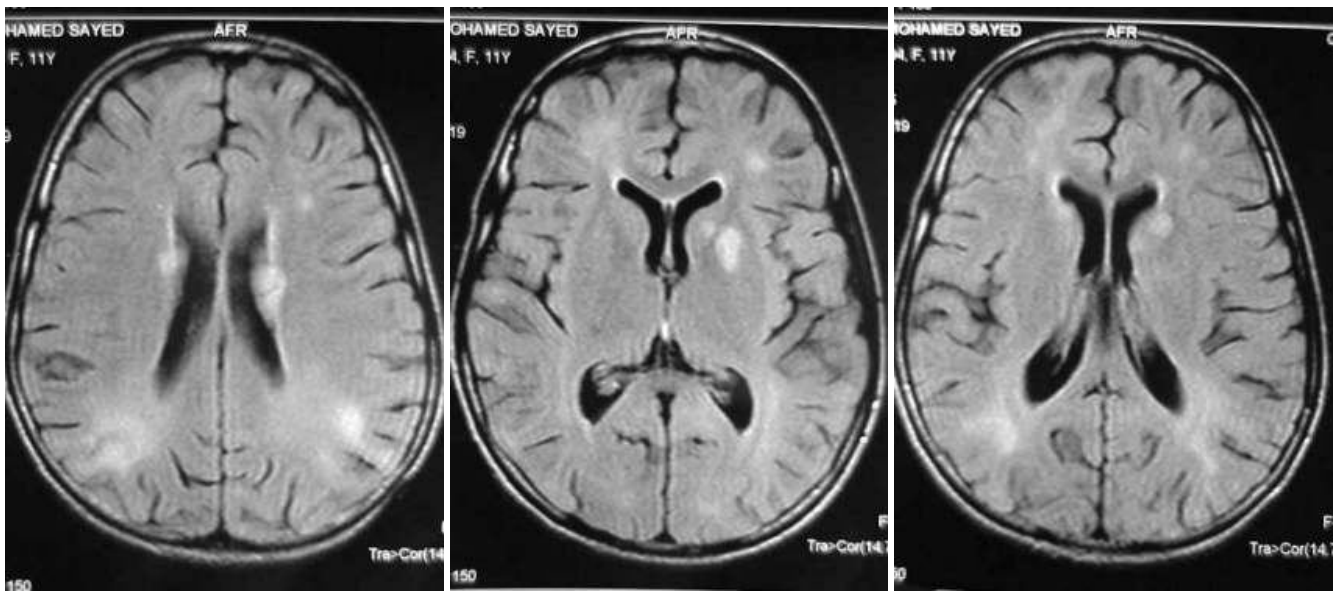
9 years old female patient presented clinically with mental subnormality, and Lennox Gastaut syndrome. The patient's family gave a history of west syndrome when the child was few months of age.

### RADIOLOGICAL FINDINGS

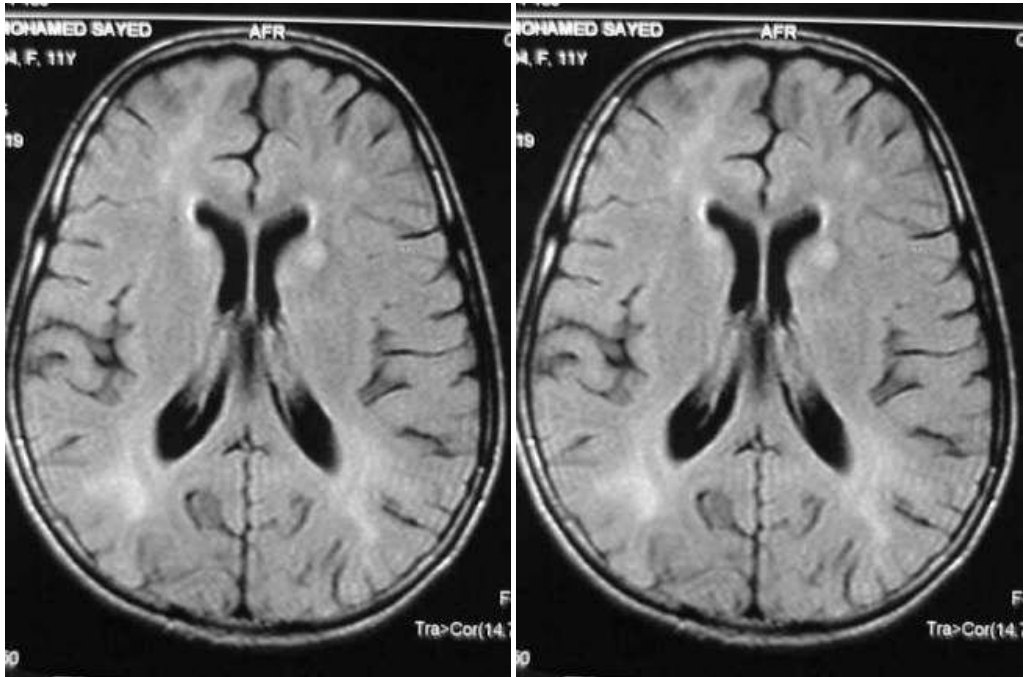
#### RADIOLOGICAL FINDINGS



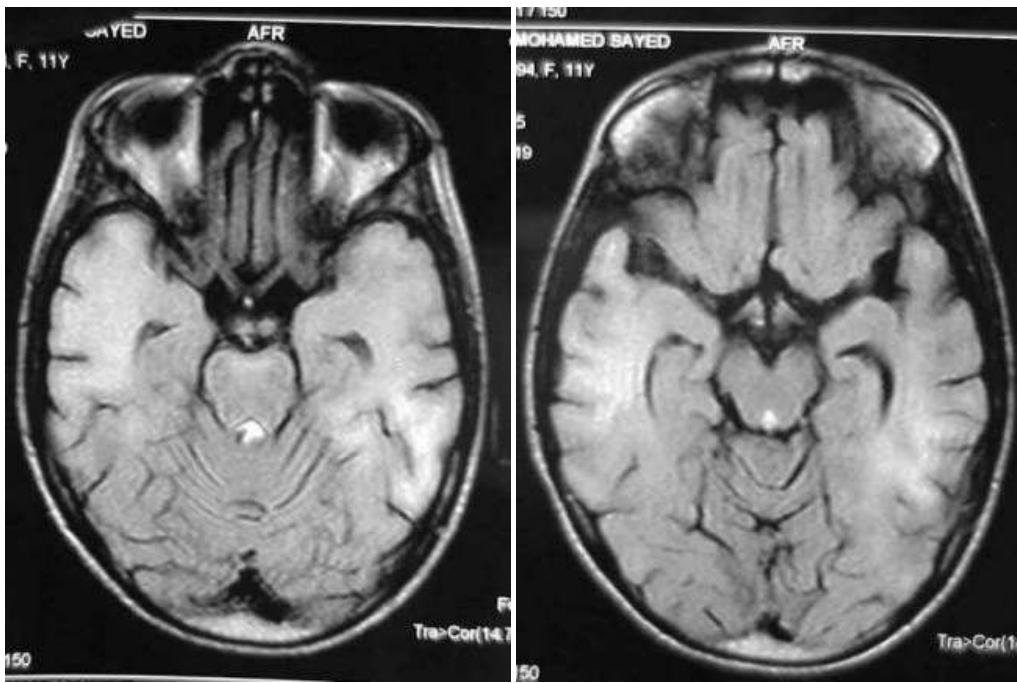
**Figure 1. Precontrast MRI T1 images showing bilateral subependymal nodules affecting the frontal horns and body of the lateral ventricles. A Cortical tuber can be seen in the occipito-parietal junction, it is hypointense, wedge shaped and involve gray matter and contiguous white matter. The wedge-shaped white matter lesions have their apex near the ventricle and their base at the cortex or at the cortical tuber. Two or more adjacent gyri are affected and appeared lissencephalic, notice gyral broadening and thickening. At histologic examination the laminar architecture of affected cortex is completely disorganized. Some scattered focal hypointense white matter changes are seen.**



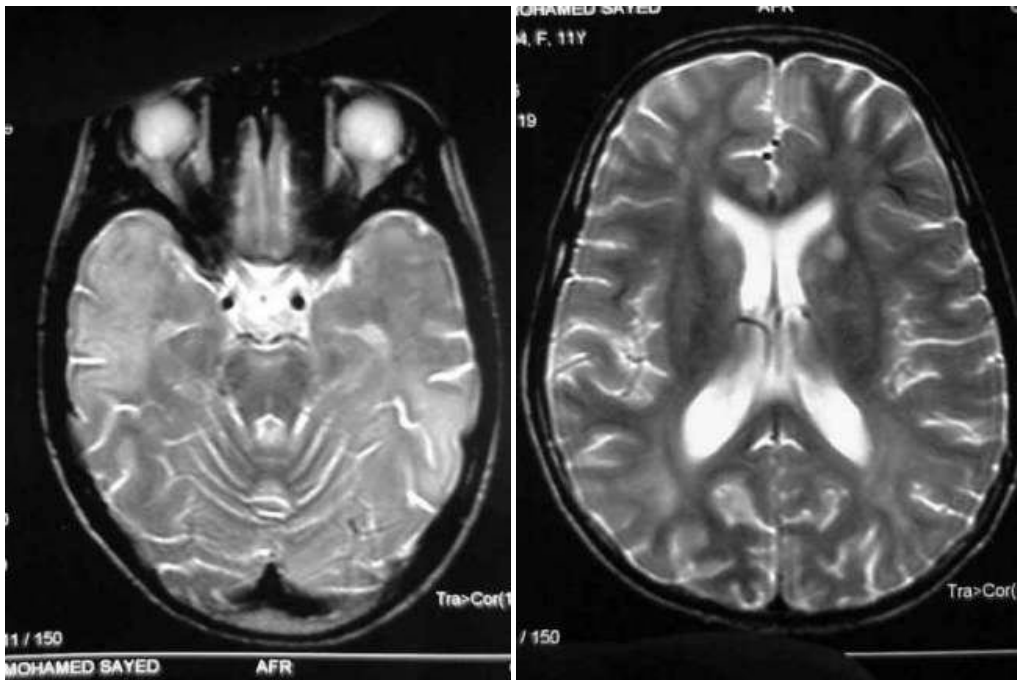
**Figure 2. MRI FLAIR images showing bilateral subependymal nodules affecting the frontal horns and body of the lateral ventricles. Bilateral wedge shaped, hyperintense cortical tubers can be seen in the occipito-parietal junction and the frontal area. The tubers involve gray matter and contiguous white matter. Two or more adjacent gyri are affected and appeared lissencephalic, notice gyral broadening and thickening. At histologic examination the laminar architecture of affected cortex is completely disorganized. Some scattered focal hyperintense white matter changes are seen. The wedge-shaped white matter lesions have their apex near the ventricle and their base at the cortex or at the cortical tuber.**



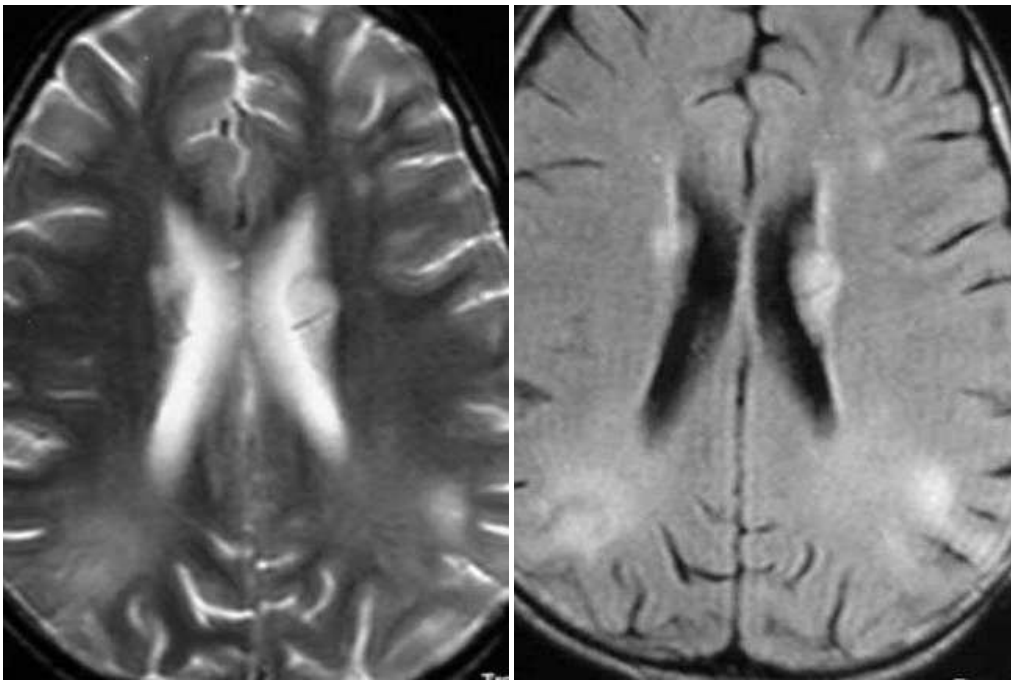
**Figure 3. MRI FLAIR images showing bilateral subependymal nodules affecting the frontal horns and body of the lateral ventricles. Bilateral wedge shaped, hyperintense cortical tubers can be seen in the occipito-parietal junction and the frontal area. The tubers involve gray matter and contiguous white matter. Two or more adjacent gyri are affected and appeared lissencephalic, notice gyral broadening and thickening. At histologic examination the laminar architecture of affected cortex is completely disorganized. Some scattered focal hyperintense white matter changes are seen. The wedge-shaped white matter lesions have their apex near the ventricle and their base at the cortex or at the cortical tuber.**



**Figure 4. MRI FLAIR images showing bilateral cortical tubers in the temporal lobes. The tubers are wedge shaped, hyperintense and involve the cortical gray matter and the adjacent white matter. The cortex is broadened, thickened, lissencephalic and pachygyric. Notice the periventricular, periaqueductal white matter changes. The wedge-shaped white matter lesions have their apex near the ventricle and their base at the cortex or at the cortical tuber.**



**Figure 5. MRI T2 images showing bilateral cortical tubers in the temporal lobes. The tubers are wedge shaped, hyperintense and involve the cortical gray matter and the adjacent white matter. The cortex is broadened, thickened, lissencephalic and pachygyric. Notice the periventricular, periaqueductal white matter changes. The wedge-shaped white matter lesions have their apex near the ventricle and their base at the cortex or at the cortical tuber.**



**Figure 6. MRI T2 (A) and FLAIR (B) images showing bilateral cortical tubers in the temporal lobes. The tubers are wedge-shaped, hyperintense and involve the cortical gray matter and the adjacent white matter. The cortex is broadened, thickened, lissencephalic and pachygyric. Notice the scattered focal and diffuse white matter changes. The wedge-shaped white matter lesions have their apex near the ventricle and their base at the cortex or at the cortical tuber.**

**Box 1. The white matter changes seen in tuberous sclerosis are of two types**

1. Radial curvilinear bands, straight or wedge-shaped bands, and nodular foci are found. Radial white matter lesions run from the ventricle through the cerebral mantle to the normal cortex or cortical tuber, wedge-shaped white matter lesions have their apex near the ventricle and their base at the cortex or at the cortical tuber, and nodular foci are located in the deep white matter. White matter lesions are composed of clusters of dysplastic giant and heterotopic cells, with gliosis and abnormal nerve fiber myelination.<sup>1</sup> These anomalies are almost identical to those of the inner core of the cortical tubers. The site, shape, and histopathologic findings of white matter lesions confirm that TSC is a disorder of both histogenesis and cell migration.
2. These are focal, single or multiple lesions, always in the deep or periventricular white matter.<sup>9</sup>

**DIAGNOSIS:**

**DIAGNOSIS: TUBEROUS SCLEROSIS**

**DISCUSSION**

**DISCUSSION**

Tuberous sclerosis is a hereditary disorder characterized by the development of early in childhood of hamartomas, malformations and congenital tumours of the CNS, skin and viscera. The pathological changes of tuberous sclerosis are widespread and include lesions in the brain, skin, bone, retina, skin and others. Clinically it is characterized by the occurrence of epilepsy, mental retardation and adenoma sebaceous in various combination.

Tuberous sclerosis (TS) is one of the most common phakomatoses. Its occurrence is around 1-20:500,000 births<sup>1</sup>, and Donegani et al.<sup>2</sup>, based on autopsy records, estimate its prevalence at 1:10,000. Ahlsen et al.<sup>3</sup> in a study carried out in Sweden on a population up to 20 years old, observed a prevalence of 1: 12,900 with a peak of 1:6,800 in the 11-15-year age group. TS is inherited as an autosomal dominant disorder with high penetrance and variable expressivity, with no racial or sexual predilection. As many as 60% of cases have been described as sporadic, resulting from spontaneous genetic mutations in the offspring of healthy parents.<sup>4</sup> The number of true sporadic cases is now decreasing as the parents of affected children undergo ocular fundoscopy and renal and cardiac echography.<sup>5</sup> TS, like every phakomatosis, can be defined as a primary cytologic dysgenesis.<sup>6</sup> The genetic disorder has been identified, with the TSC1 and TSC2 genes localized respectively on chromosome 9 band q 34.3 and chromosome 16 band p 13.3.<sup>7,8</sup> Nevertheless, a specific molecular marker that would allow recognition of the asymptomatic and quasi-asymptomatic cases has not yet been found.<sup>9</sup> TS is a multiorgan disease (skin, retina, lungs, heart,



skeleton, and kidneys) involving the embryonic ectoderm, mesoderm, and endoderm. The central nervous system (CNS) is always affected, and CNS disease is often the first indicator of the disorder.<sup>10</sup> The primary anomaly of TS is an abnormal differentiation and growth of the neuronal and glial cells, associated with migration anomalies and disorganization of the cortical architecture, formation of tumor-like cell clusters [hamartias or hamartomas according to Gomez<sup>11</sup>], and rarely neoplasia. The presence of cell dysplasia, however, differentiates phakomatoses from CNS malformations.<sup>6</sup>

- Genetic causes

TSC is inherited in an autosomal dominant pattern. An affected parent has a 50% chance of transmitting the disease to offspring. There are a significant number of sporadic mutations, estimated to occur in approximately two thirds of cases.<sup>9</sup>

Two genes, *TSC1* and *TSC2*, have been identified. *TSC1* is located on chromosome 9 and was identified in 1997. This gene encodes for the protein hamartin. The protein tuberin is encoded by the gene *TSC2*. *TSC2*, located on chromosome 16, was the first TSC gene discovered in 1993. Approximately 50% of cases are due to *TSC1*, and the remaining 50% are due to *TSC2*. Of sporadic cases, 75% are due to a mutation in the *TSC2* gene.<sup>9</sup>

Table 1. Genetics of tuberous sclerosis

Gene	Gene Location	Gene product	Comment
<i>TSC1</i>	Chromosome 9	Hamartin	Recent findings support the hypothesis that the <i>TSC2</i> gene and perhaps the <i>TSC I</i> gene act as tumor suppressors. When the <i>TSC</i> mutation occurs, the defective gene product of the <i>TSC</i> mutation is unable to suppress the tumor growth caused by a random somatic cell mutation that produces an oncogene stimulating the formation and growth of hamartomas. <sup>9</sup>
<i>TSC2</i>	Chromosome 16	Tuberin	

At the present time, TSC is a clinical diagnosis, because genetic testing currently is not routinely available. Genetic mutation analysis is available on a research basis. Family members may also be tested on a clinical basis if a mutation is detected. Information regarding this topic is available at the following website: [www.geneclinics.org](http://www.geneclinics.org)

Criteria for germline mosaicism have recently been outlined. Parents who have no evidence of either major or minor criteria of TSC and also have 2 or more children affected with TSC are said to meet the criteria for germline mosaicism. For this reason, parents who have none of the manifestations of TSC but do have 1 child affected with TSC should be counseled about a 1-2% chance of having another child affected with TSC. The incidence of germline mosaicism is estimated to be approximately 10-25%.<sup>9</sup>

### RADIOLOGICAL PATHOLOGY OF TUBEROUS SCLEROSIS

Pathologically tuberous sclerosis is characterized by the presence of Cortical tubers, Subependymal nodule, Giant cell astrocytoma, White matter lesions and Deep white matter lesions.

Table 2. Pathology of tuberous sclerosis

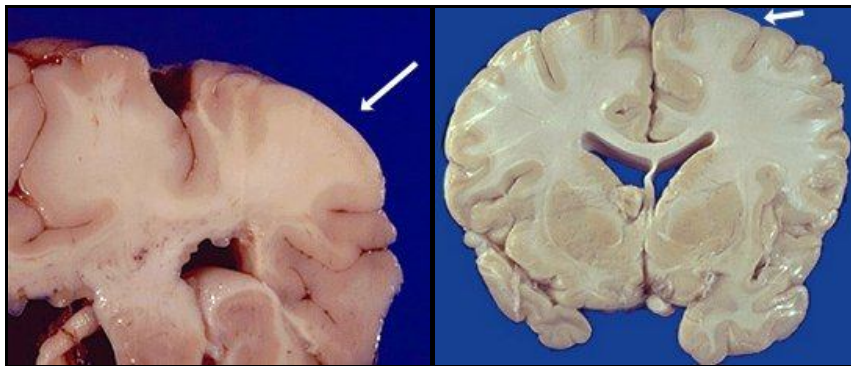
Pathology	Comment
<b>Cortical tubers</b>	They involve gray matter and contiguous white matter. Sometimes two or more adjacent gyri are affected. They may cause gyral broadening and thickening. At histologic examination the laminar architecture of affected cortex is completely disorganized. Normal neurons and normal glial cells are scanty and abundant undifferentiated neuroepithelial cells and atypical neuron-like cells are observed, with rare clusters of abnormal bizarre glial cells. The subcortical white matter adjacent to a cortical tubers is abnormal, and is usually with defective myelination of neural fibers and gliosis. <sup>13</sup> The cortical tubers surface is smooth but becomes depressed due to degenerative phenomena with cellular loss in the affected cortex. Dystrophic calcifications are infrequently present in cortical tubers
<b>Subependymal nodule</b>	Typically located in the subependymal walls of the lateral ventricles, usually bilateral and mainly at the foramina of Monro. subependymal nodules have never been observed in the third ventricle. <sup>9,11</sup> Their number and size are quite variable. Subependymal nodules contain the same kind of cell abnormalities as cortical tubers, but with very many large, bizarre glial cells, fusiform cells, and undifferentiated neuroectodermal cells. However, neuron-like cells are scant. Much vascular and fibroglial stroma with accumulations of calcium deposits is often found. Focal hemorrhages and necrosis have also been reported. <sup>9,11,16</sup>
<b>Giant cell astrocytoma</b>	Subependymal Giant-Cell Astrocytomas are clinically and histopathologically benign. <sup>20</sup> They grow slowly, have no surrounding edema, are noninvasive, and rarely show malignant degeneration. <sup>21</sup> There are no qualitative histopathologic differences between subependymal nodules and Subependymal Giant-Cell

	Astrocytomas. Like subependymal nodules, Subependymal Giant-Cell Astrocytomas contain large amounts of undifferentiated giant cells or abnormally differentiated cells resembling astrocytes or spongioblasts, together with a few abnormal neurons. The fibrovascular stroma contains dystrophic calcifications and cystic or necrotic areas of degeneration. <sup>22</sup> Subependymal Giant-Cell Astrocytomas may originate from subependymal nodules located near the foramen of Monro. Recent findings support the hypothesis that the TSC2 gene and perhaps the TSC I gene act as tumor suppressors. When the TSC mutation occurs, the defective gene product of the TSC mutation is unable to suppress the tumor growth caused by a random somatic cell mutation that produces an oncogene stimulating the formation and growth of hamartomas. <sup>9</sup>
<b>White matter lesions</b>	Radial curvilinear bands, straight or wedge-shaped bands, and nodular foci were found. Radial white matter lesions run from the ventricle through the cerebral mantle to the normal cortex or cortical tuber, wedge-shaped white matter lesions have their apex near the ventricle and their base at the cortex or at the cortical tuber, and nodular foci are located in the deep white matter. White matter lesions are composed of clusters of dysplastic giant and heterotopic cells, with gliosis and abnormal nerve fiber myelination. <sup>1</sup> These anomalies are almost identical to those of the inner core of the cortical tubers. The site, shape, and histopathologic findings of white matter lesions confirm that TSC is a disorder of both histogenesis and cell migration.
<b>Deep white matter lesions</b>	These are focal, single or multiple lesions, always in the deep or periventricular white matter. <sup>9</sup>

- **Cortical tubers**

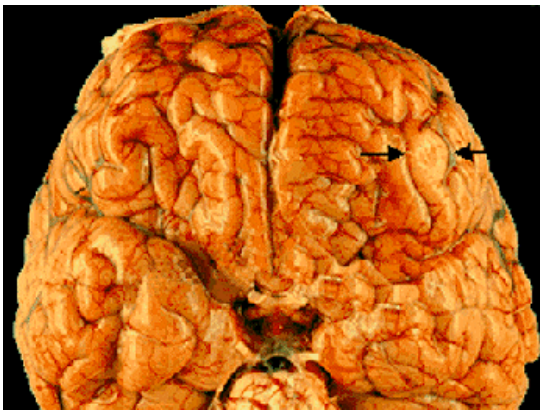Tuberous sclerosis histopathological features are not dissimilar to those of cortical dysplasia. In tuberous sclerosis, however, severe gliosis may be noted in the subpial area.

In tuberous sclerosis, the most common clinical presentation is seizure, occurring in more than 80% of cases.<sup>9</sup> The brain characteristically reveals multiple nodules ("tuber") in the crest of cerebral gyri. The nodules are generally most abundant in the frontal lobe. The involved cortex is firm in consistency and shows some blurring of the junction between the cortex and white matter. Histologically, the subpial area is thickened by proliferating astrocytes that may be large and bizarre with abundant processes. Laminar organization of the cortex is obscured by numerous large, irregularly oriented neurons with coarsely granular Nissl substance. In addition, there are, large cells with abundant, pale cytoplasm and large, round nuclei with prominent nucleoli. These cells are free of Nissl substance and some seem to be of astrocytic lineage because of their GFAP immunopositivity. They are more frequently found in the white matter, occasionally arranged in clusters. Overall, these features are not dissimilar to those of cortical dysplasia of Taylor. In tuberous sclerosis, however, severe gliosis may be noted in the subpial area.<sup>9</sup>



**Figure 7. Postmortem specimens showing cortical tubers, the affected gyri are abnormally broad and flat.**

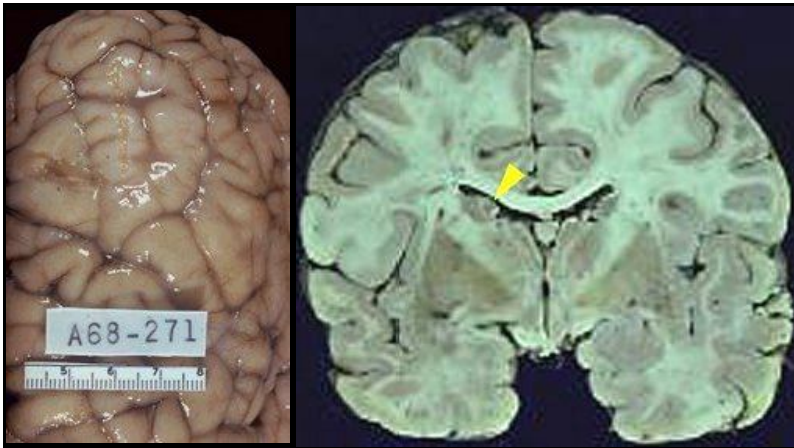
Cortical tubers involve gray matter and contiguous white matter. Sometimes two or more adjacent gyri are affected. They may cause gyral broadening and thickening. On MRI, the affected cortex is frequently pseudopachygyric, but the gray matter does not show signal abnormalities on both short and long TR SE images. At histologic examination the laminar architecture of affected cortex is completely disorganized. Normal neurons and normal glial cells are scanty and abundant undifferentiated neuroepithelial cells and atypical neuron-like cells are observed, with rare clusters of abnormal bizarre glial cells.<sup>6</sup> The high cortical cellularity implies a free water loss in gray matter, and this explains the normality of the MR signal.<sup>12</sup> However, the subcortical white matter MR signal is abnormal adjacent to a cortical tuber, and is usually hyperintense on long TR SE images. This is due to defective myelination of neural fibers and gliosis.<sup>13</sup> The subcortical white matter in newborns and very young infants appears hyperintense on TIWI and hypointense on T2WI. This can be explained by a greater amount of free water in the unmyelinated white matter compared to the inner core of the cortical tubers.<sup>14</sup> The cortical tubers surface is smooth but becomes depressed due to degenerative phenomena with cellular loss in the affected cortex. Dystrophic calcifications cause marked focal hypointensity on T2WI.<sup>11</sup> This is not common in cortical tubers. Signal enhancement on TIWI after GD-DTPA administration is reported in less than 5% of cases.<sup>15</sup> Follow-up MRI might show an increase in the number and/or size, or increase of signal enhancement after GD-DTPA of cortical tubers.



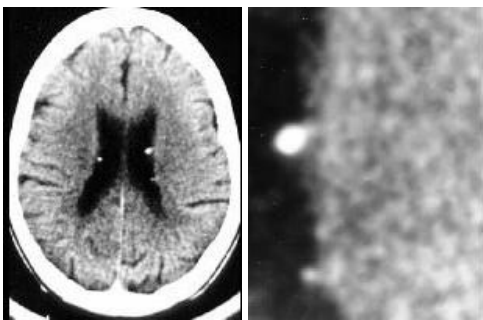
**Figure 8. Postmortem specimens showing cortical tubers with flat surface**

- **Subependymal nodule**

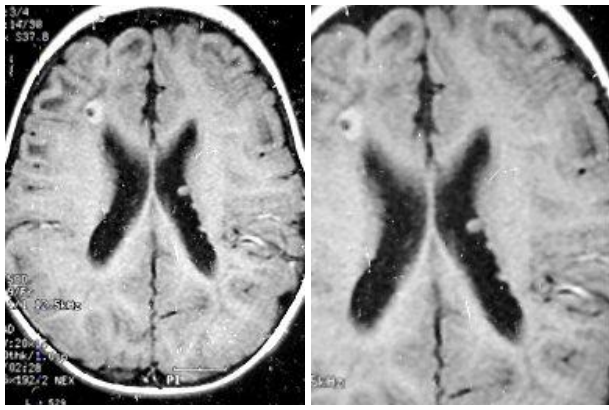
Typically located in the subependymal walls of the lateral ventricles, usually bilateral and mainly at the foramina of Monro. subependymal nodules have never been observed in the third ventricle.<sup>9,11</sup> Their number is quite variable in each patient, and their size from a few millimeters to over 1 cm. subependymal nodules contain the same kind of cell abnormalities as cortical tubers, but with very many large, bizarre glial cells, fusiform cells, and undifferentiated neuroectodermal cells. However, neuron-like cells are scant. Much vascular and fibroglial stroma with accumulations of calcium deposits is often found. Focal hemorrhages and necrosis have also been reported.<sup>9,11,16</sup>



**Figure 9. Postmortem specimens showing cortical tubers in A and subependymal tubers in B**

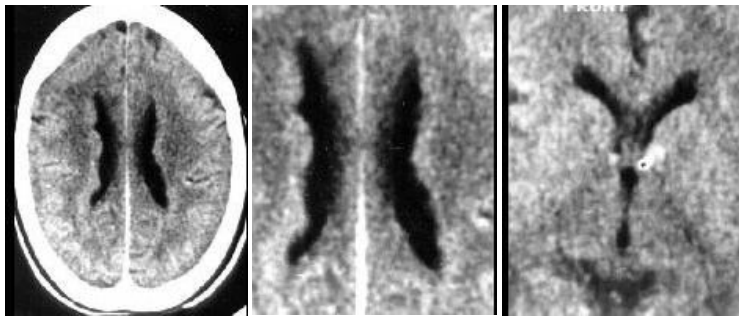


**Figure 10. CT scan precontrast showing subependymal calcified nodules projecting into the ventricular cavity (candle guttering)**



**Figure 11. MRI T1 images showing cortical tuber, radial white matter lesions and subependymal nodules forming candle guttering. The cerebral cortex appears lissencephalic and pachygyric especially over the frontal lobes.**

The brain is usually normal in size, but several or many hard nodules occur on the surface of the cortex or along the subependymal covering of the ventricular system. These nodules are smooth, rounded or polygonal and project slightly above the surface of the neighboring cortex. They are whitish in colour and firm.



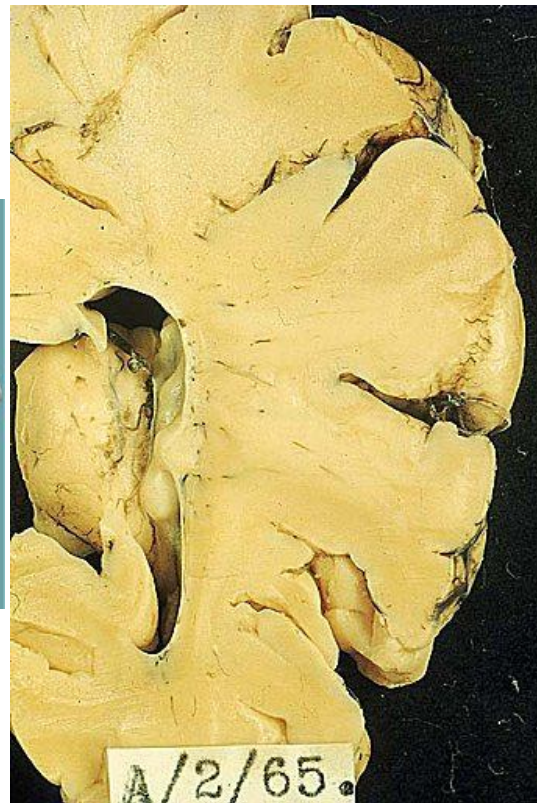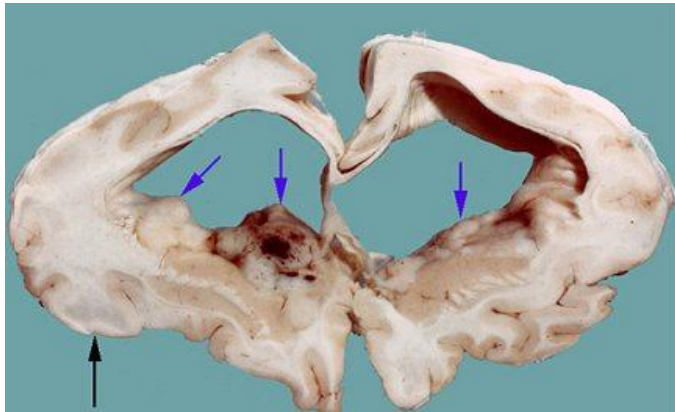
**Figure 12. CT scan precontrast in two cases of tuberous sclerosis showing subependymal noncalcified nodules projecting into the ventricular cavity (A,B) and a calcified nodule at the foramen of Monro (C)**

Histopathologically, the nodules are characterized by the presence of a cluster of atypical glial cells in the center and giant cells in the periphery. The nodules are frequently, but not necessarily, calcified. These nodules occasionally give rise to giant cell astrocytoma when they are large in size.

On MRI, the subependymal nodules appear to impinge on the ventricular cavity from the subependymal walls. Their signal depends mainly on the presence and amount of mineral deposits. If calcifications are widespread, subependymal nodules are very hypointense in all pulse sequences, occasionally surrounded by a hyperintense rim on long TR; otherwise, they are usually isointense to white matter on short TR and slightly hyperintense on long TR.<sup>9,12</sup> Calcifications are rare in newborns and infants, making diagnosis difficult both by CT and MRI.<sup>14</sup> However, in children over 1 year and in adults, calcification of the stroma is usual, and CT, owing to its greater ability to detect calcium, has been considered best for assessment of subependymal nodules.<sup>17</sup> Nevertheless, MR gradient echo pulse sequences with short flip angle are equally useful because of the magnetic susceptibility of calcified lesions, which appear profoundly hypointense.<sup>18</sup> After contrast medium, subependymal nodules do not enhance on CT, whereas on MRI they show nodular or annular hyperintensity.<sup>16</sup> This may be due to higher MRI sensitivity and also to enhancement of uncalcified gliovascular stroma after GD-DTPA administration, while the calcified component remains markedly hypointense.<sup>15,25</sup>

The tuberous sclerosis nodules are variable in size and might attain a huge size. On sectioning the brain, sclerotic nodules may be found in the subcortical gray matter, the white matter and the basal ganglia. The lining of the lateral ventricles is frequently the site of numerous small nodules that project into the ventricular cavity (candle gutterings). Sclerotic nodules are characteristically found in or near the foramen of Monro and commonly induce hydrocephalus. The cerebellum, brain stem, and spinal cord are less frequently involved.



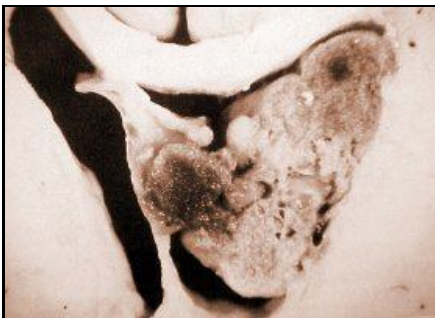


**Figure 13. (A,B) In tuberous sclerosis the lining of the lateral ventricles is frequently the site of numerous small nodules that project into the ventricular cavity (candle gutterings) (blue arrows in A). Also notice cortical tubers (black arrow in A)**

- **Giant cell astrocytoma**

The subependymal giant cell astrocytoma (SGCA) is another low-grade (WHO grade 1) astrocytic neoplasm.<sup>13</sup> This neoplasm is most commonly seen (>90%) in association with clinical or radiologic evidence for tuberous sclerosis.<sup>13</sup> Tuberous sclerosis is an autosomal dominant phakomatosis, characterized by disseminated hamartomas of the CNS, kidneys, skin, and bone. True neoplasms also occur, with approximately 15% of patients developing SGCA. The tumor is sometimes called the intraventricular tumor of tuberous sclerosis. The lesion usually presents in the teens or 20s.<sup>25</sup>

Subependymal Giant-Cell Astrocytomas are clinically and histopathologically benign<sup>20</sup>. They grow slowly, have no surrounding edema, are noninvasive, and rarely show malignant degeneration.<sup>21</sup> There are no qualitative histopathologic differences between subependymal nodules and Subependymal Giant-Cell Astrocytomas. Like subependymal nodules, Subependymal Giant-Cell Astrocytomas contain large amounts of undifferentiated giant cells or abnormally differentiated cells resembling astrocytes or spongioblasts, together with a few abnormal neurons. The fibrovascular stroma contains dystrophic calcifications and cystic or necrotic areas of degeneration.<sup>22</sup> Subependymal Giant-Cell Astrocytomas may originate from subependymal nodules located near the foramen of Monro.<sup>25</sup>



**Figure 14. Close-up view of the frontal horn of the left lateral ventricle, showing a giant cell astrocytoma filling the anterior horn in a 15-year-old boy with tuberous sclerosis.**

On MRI, uncalcified Subependymal giant-cell astrocytomas are isointense to white matter on short TR images: calcified components are hypointense. On long TR images the signal increases in the parenchymal component of the lesion, whereas calcifications become profoundly hypointense on T2WI. Serpentine, linear, or punctate signal voids believed to be due to dilated tumor vessels.<sup>9</sup> Subependymal Giant-Cell Astrocytomas enhance on CT after iodinated contrast medium administration, whereas subependymal nodules do not increase in density. This was believed to be due to a breakdown of the

blood-brain barrier in the Subependymal Giant-Cell Astrocytomas<sup>14</sup>, and therefore CT was considered best for differential diagnosis. Both Subependymal Giant-Cell Astrocytomas and subependymal nodules located at the foramen of Monro show nodular enhancement on MRI after GD-DTPA.<sup>15</sup> Recent findings support the hypothesis that the TSC2 gene and perhaps the TSC1 gene act as tumor suppressors. When the TSC mutation occurs, the defective gene product of the TSC mutation is unable to suppress the tumor growth caused by a random somatic cell mutation that produces an oncogene stimulating the formation and growth of hamartomas.<sup>25</sup>

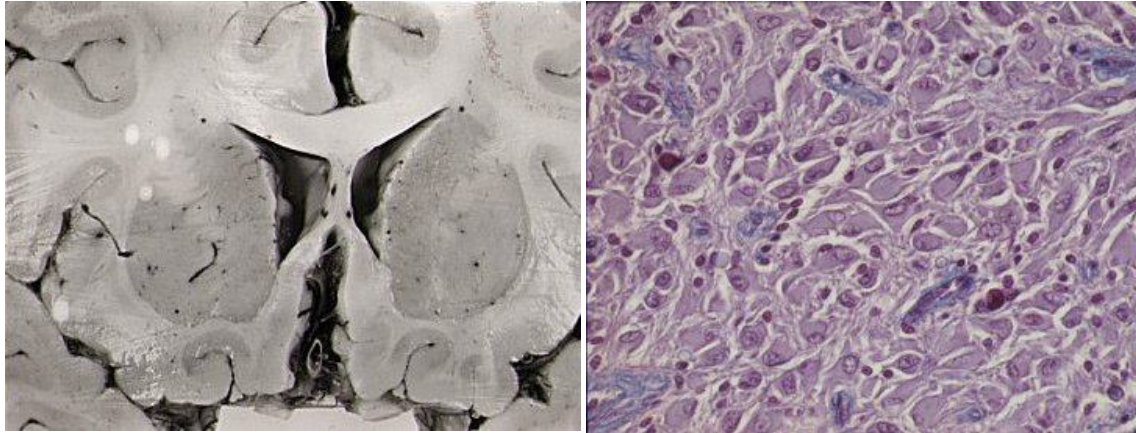


Figure 15. **Giant cell astrocytoma.**

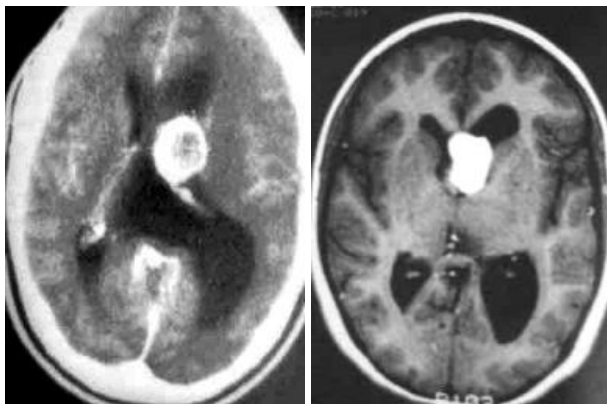


Figure 16. **Subependymal giant cell astrocytoma. Axial T1-weighted gadolinium-enhanced MR image (A) and postcontrast CT scan (B) show a well-demarcated intraventricular mass in the left frontal horn at the foramen of Monro. The lesion is growing into the ventricle as a polypoid lesion, attached to the head of the caudate nucleus.**

Grossly the lesion is a well-demarcated mass. It is almost always in the lateral ventricle, near the foramen of Monro. The lesion is fixed to the head of the caudate nucleus but does not spread through it. As the name implies, an intact layer of ependyma covers the tumor. Thus cerebrospinal fluid dissemination and spread through the brain are not typical. Histologically the lesion contains giant cells that have been variously described as astrocytes, neuronal derivatives, or something in between. The histology is distinctive and may suggest not only this particular tumor, but also the association with tuberous sclerosis that is so common. Calcification is frequent.<sup>9,25</sup>

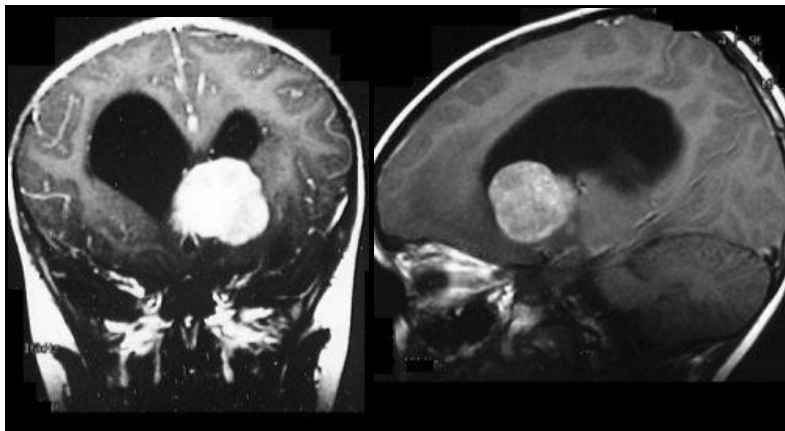


Figure 17. **Subependymal giant cell astrocytoma.**

The appearance of SGCA on imaging studies is usually typical, characteristic, and almost pathognomonic. First, most patients show other features of tuberous sclerosis, including cortical tubers and subependymal nodules. Second, the tumor location is almost unique-intraventricular, near the foramen of Monro, and attached to the head of the caudate nucleus. Enhancement is

often present on both CT and MR. Calcification is common and may be in the form of irregular chunks and nodules. The lesion has a polypoid shape as it protrudes into the lumen of the lateral ventricle. Secondary changes of hydrocephalus, from obstruction of the foramen of Monro, are frequent. Ventricular enlargement may be unilateral (on the side of the tumor) or bilateral.<sup>25</sup>

- **White matter lesions**

White matter lesions are dysplastic heterotopic neurons seen as migration lines running from through the cerebral mantle to a normal cortex or a cortical tuber. They are wedge-shaped with their apex near the ventricle and their base at the cortex or at the cortical tuber. Gliosis is commonly present in white matter lesion of tuberous sclerosis.<sup>9</sup>

Radial curvilinear bands, straight or wedge-shaped bands, and nodular foci are found. Radial white matter lesions run from the ventricle through the cerebral mantle to the normal cortex or cortical tuber, wedge-shaped white matter lesions have their apex near the ventricle and their base at the cortex or at the cortical tuber, and nodular foci are located in the deep white matter. White matter lesions are composed of clusters of dysplastic giant and heterotopic cells, with gliosis and abnormal nerve fiber myelination.<sup>1</sup> These anomalies are almost identical to those of the inner core of the cortical tubers. Therefore, on MRI, the white matter lesions are similarly hyperintense on long TR and isointense or hypointense on short TR images. No signal enhancement with GD-DTPA contrast WAS found. The site, shape, and histopathologic findings of white matter lesions confirm that TSC is a disorder of both histogenesis and cell migration. Heterogeneous gray structures in the white matter without calcification may also be present.<sup>9</sup>

- **Deep white matter lesions**

These are focal, single or multiple lesions, always in the deep or periventricular white matter. On MRI they are isointense to the cerebrospinal fluid in all pulse sequences, sometimes surrounded by a hyperintense rim on T2WI, without mass effect.

**Table 3. Summary of radiological signs in tuberous sclerosis**

**MRI or CT scan of the brain**

- An MRI of the brain is recommended for the detection and follow-up of cortical tubers, Subependymal nodule, and giant cell astrocytoma. Perform MRI during the initial diagnostic work-up and also every 1-3 years in children with TSC. The MRI may be performed less frequently in adults without lesions and as clinically indicated in adults with lesions. Also, perform an MRI in family members if their physical examinations are negative or not definitive for a diagnosis. MRI is preferred over CT scan due to improved visualization and no risk of radiation with repeat examinations.
- Cortical tubers, best detected on T2-weighted images, often occur in the gray-white junction. On T2-weighted images, they have increased signal and often are in wedged (tuber) or linear shapes (radial migration lines). Conversely, they have decreased signal uptake on T1-weighted imaging. Previously thought to be pathognomonic, they no longer are considered specific for TSC since isolated cortical dysplasia may have a similar radiographic appearance. There appears to be a correlation between the number of tubers on MRI and severity of mental retardation or seizures.
- Subependymal nodules (SEN) are located in the ventricles and often become calcified. The lesions are detected best by CT scan, although they sometimes are noted on MRI or plain film if calcified. They give a candle-dripping appearance.
- Subependymal nodule may grow and give rise to a giant cell astrocytoma. A giant cell astrocytoma may cause obstruction with evidence of hydrocephalus or mass effect in some patients. These lesions usually appear in the region of the foramen of Monro, are partially calcified, and often are larger than 2 cm. Detection of a giant cell astrocytoma is slightly more sensitive with MRI than CT scan.

- **Tuberous sclerosis as a disorder of neuronal cell proliferation, differentiation and migration**

Tuberous sclerosis is a primary cell dysplasia resulting from embryonic ectoderm, mesoderm, and endoderm anomalies. In the CNS they involve neuroepithelial cells, which also show disordered cell migration and organization. All the lesions are hamartias or hamartomas, and histologic differences among them are slight and quantitative; therefore, all of these lesions may change with time. The arrest of cell migration at different stages explains the different sites of the various anomalies. Subependymal nodules and periventricular white matter anomalies reflect a failure of migration, white matter lesions an interruption, and cortical tubers an abnormal completion of migration with disordered cortical architecture. Subependymal giant-cell astrocytomas are the only neoplastic growth, and they derive from subependymal nodules that have some proliferative potential.<sup>9</sup>

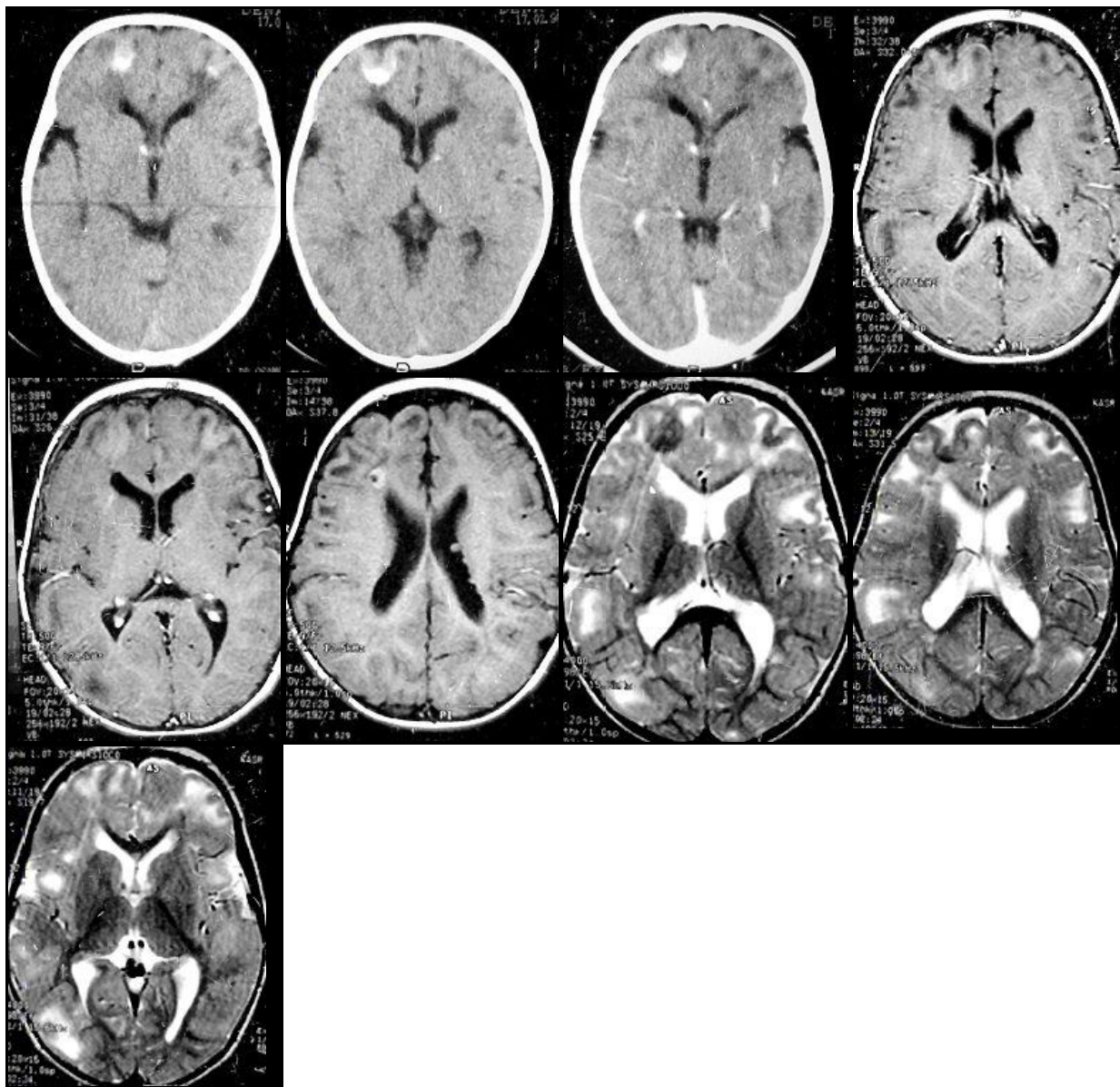
Disorders such as tuberous sclerosis, in which both tumor development and areas of cortical dysplasia are seen, might be a differentiation disorder. The brain manifestations of this disorder include hamartomas of the subependymal layer, areas of cortical migration abnormalities (tubers, cortical dysgenesis), and the development of giant-cell astrocytomas in upwards of 5% of affected patients. Two genes for tuberous sclerosis have been identified: TSC1 (encodes for Hamartin) has been



localized to 9q34<sup>25</sup>, and TSC2 (encodes for Tuberin) has been localized to 16p13.3.<sup>25</sup>

**Table 4. Tuberous sclerosis as a disorder of neuronal cell proliferation, differentiation and migration**

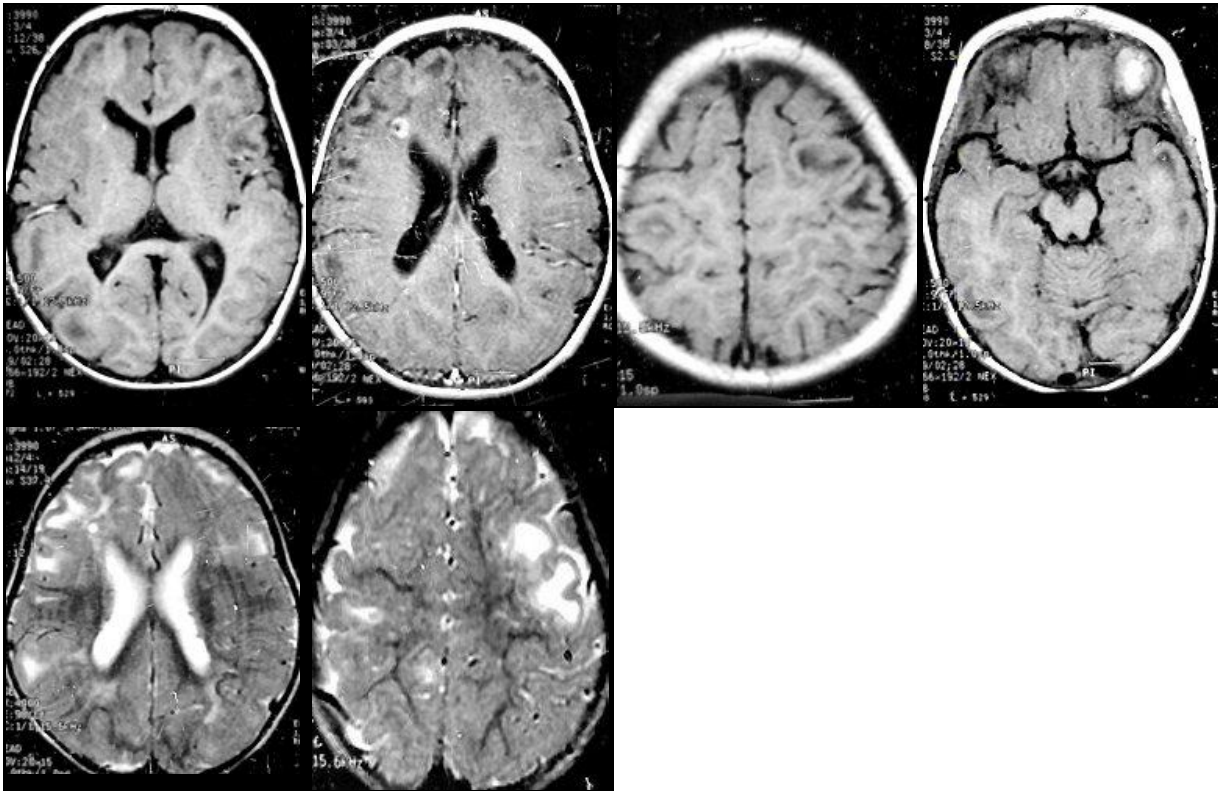
Pathology	Comment
Subependymal nodules and periventricular white matter anomalies.	Failure of migration.
White matter lesion	An interruption of migration.
Cortical tubers.	An abnormal completion of migration with disordered cortical architecture.
Subependymal giant-cell astrocytomas ( the only neoplastic growth)	They derive from subependymal nodules that have some proliferative potential.



**Figure 18. A,B CT scan precontrast and C, CT scan postcontrast study, D,E,F precontrast MRI T1 images, G,H,I MRI T2 images. Notice the calcified cortical tuber in the left frontal region. The tuber is hyperdense in CT scan studies and hypointense on the MRI T2 studies (due to calcification). The precontrast T1 hyperintensity observed in the subcortical white matter in (E,F,G) could be due to defective myelination. The cerebral cortex appears lissencephalic and pachygyric especially over the frontal lobes. The cortical tubers surface is smooth but depressed due to degenerative phenomena with cellular loss in the affected cortex. The subcortical white matter adjacent to the cortical tubers shows the characteristic radial white matter lesions, they are wedge-shaped white matter lesions with their apex near the ventricle and their base at the cortex or at the cortical tuber. These white matter lesions are hyperintense on the T2 MRI images and hypointense on the MRI T1 images. They can also be seen as hypodense regions in CT scan studies. Radial white matter lesions are dysplastic heterotopic neurons**



seen as migration lines running through the cerebral mantle to a normal cortex or a cortical tuber. Subependymal nodules are also seen in (F) forming what is called candle guttering.



**Figure 19. MRI T1 images (A,B,C,D) and MRI T2 images (E,F). A case of tuberous sclerosis, notice that cortical tubers have broad, irregular, and slightly depressed surface and most marked in the frontoparietal regions. The brain is lissencephalic and pachygyric. Also notice the characteristic radial white matter lesions, they are wedge-shaped white matter lesions with their apex near the ventricle and their base at the cortex or at the cortical tuber. These white matter lesions are hyperintense on the T2 MRI images and hypointense on the MRI T1 images. Radial white matter lesions are dysplastic heterotopic neurons seen as migration lines running through the cerebral mantle to a normal cortex or a cortical tuber. The precontrast T1 hyperintensity observed in the subcortical white matter in (E) could be due to defective myelination or hypercellularity (Normal neurons and normal glial cells are scanty and abundant undifferentiated neuroepithelial cells and atypical neuron-like cells are seen as migration lines running through the cerebral mantle to a normal cortex or a cortical tuber, these neurons might have a high nuclear to cytoplasmic ratio, with little extracellular water resulting in precontrast T1 hyperintensity and T2 hypointensity)**

- **Overview of normal neuronal migration**

At the most rostral end of the neural tube in the 40- to 41 -day-old fetus, the first mature neurons, Cajal-Retzius cells, begin the complex trip to the cortical surface. Cajal-Retzius cells, subplate neurons, and corticopetal nerve fibers form a preplate.<sup>25</sup> The neurons generated in the proliferative phase of neurodevelopment represent billions of cells poised to begin the trip to the cortical surface and to form the cortical plate. These neurons accomplish this task by attaching to and migrating along radial glia in a process known as radial migration or by somal translocation in a neuronal process.<sup>25</sup> The radial glia extend from the ventricle to the cortical surface. In the process of migration, the deepest layer of the cortical plate migrates and deposits before the other layers. Therefore, the first neurons to arrive at the future cortex are layer VI neurons. More superficial layers of cortex then are formed—the neurons of layer V migrate and pass the neurons of layer VI; the same process occurs for layers IV, III, and II. The cortex therefore is formed in an inside-out fashion.<sup>25</sup>

A possible mode of movement in neuronal migration on glia would be the attachment of the neuroblast to a matrix secreted by either the glia or the neurons. The attachment of the neuron would be through integrin receptors, cytoskeletal-linking membrane-bound recognition sites for adhesion molecules. That attachment serves as a stronghold for the leading process and soma of the migrating neuron. Neuron movement on radial glia involves an extension of a leading process, neural outgrowth having an orderly arrangement of microtubules. Shortening of the leading process owing to depolymerization or shifts of microtubules may result in movement of the soma relative to the attachment points. This theory of movement of neurons also must include a phase of detachment from the matrix at certain sites, so that the neuron can navigate successfully along as much as 6 cm of developing cortex (the maximum estimated distance of radial migration of a neuron in the human). Finally, the movement of cells must stop at the appropriate location, the boundary between layer I and the forming cortical plate. Therefore, some stop signal must be given for the migrating neuron to detach

from the radial glia and begin to differentiate into a cortical neuron. Perhaps that signal is reelin, a protein that is disrupted in the mouse mutant *Reeler* and is expressed solely in the Cajal Retizius cells at this phase of development.<sup>25</sup>

---

## SUMMARY

---

Tuberous sclerosis complex (TSC) is the second most common neurocutaneous disease. It is inherited in an autosomal dominant fashion, although the rate of spontaneous mutation is high. Formerly characterized by the clinical triad of mental retardation, epilepsy, and facial angiofibromas, it is now recognized that TSC may present with a broad range of clinical symptoms due to variable expressivity. TSC may affect many organs, most commonly the brain, skin, eyes, heart, kidneys, and lungs. Common features include cortical tubers, subependymal nodules (SENs), subependymal giant cell astrocytomas (SEGAs), facial angiofibromas, hypomelanotic lesions (ash-leaf spots), cardiac rhabdomyomas, and renal angiomyolipomas. Two genes, *TSC1* and *TSC2*, have recently been identified. The current diagnostic criteria, however, continue to be based upon clinical manifestations.

### • Addendum

- A new version of case record of the week publication is uploaded in my web site every week (every Saturday and remains available till Friday.)
- To download the current PDF version of case record of the week publication follow the link "<http://pdf.yassermetwally.com/case.pdf>".
- To download the current software version of case record of the week publication (crow.exe) follow the link: <http://neurology.yassermetwally.com/crow.zip>
- You can also download the current version from my web site at "<http://yassermetwally.com>".
- The case is also presented as a short case in PDF format, to download the short case follow the link: <http://pdf.yassermetwally.com/short.pdf>
- At the end of each year, all the publications are compiled on a single CD-ROM, please contact the author to know more details.
- Screen resolution is better set at 1024\*768 pixel screen area for optimum display
- [Click here](#) for an archive of the previously reported cases in downloadable PDF files.
- For an archive of the previously reported cases go to [www.yassermetwally.net](http://www.yassermetwally.net), then under pages in the right panel, scroll down and click on the text entry "Downloadable case records in PDF format" and "Downloadable short cases in PDF format"
- Also to view a list of the previously published case records follow the following link (<http://wordpress.com/tag/case-record/>).

---

## REFERENCES

### References

1. Braffman BH, Bilaniuk LT, Zimmermann RA. The central nervous system manifestation of the phakomatoses. *Radiol Clin North Am* 1988;26: 773-800.
2. Donegani G, Grattarola FR, Wildi E. Tuberous sclerosis. In: Vinken PJ, Bruyn GB, eds. *The phakomatoses*. Vol. 14. *Handbook of clinical neurology*. Amsterdam: Elsevier, 1972.
3. Ahlsen G, Gilberg IC, Lindblom R, Gilberg G. Tuberous sclerosis in western Sweden. *Arch Neurol* 1994;51:76-81.
4. Sampson JR, Schahill SJ, Stephenson JBP, Mann L, Connor JM. Genetic aspects of tuberous sclerosis in the west of Scotland. *J Med Genet* 1989; 26:28-31.
5. Perelman R. *Pgdiatrie pratique: pathologie du systeme nerveux et des muscles*. Paris: Maloine, 1990.
6. Sarnat HB. *Cerebral dysgenesis. Embryology and clinical expression*. New York, Oxford: Oxford University Press, 1992.
7. Fryer AE, Chalmers AH, Connor JM, et al. Evidence that the gene for tuberous sclerosis is on chromosome 9. *Lancet* 1987;1:659-61.
8. Kandt RS, Haines L, Smith S, et al. Linkage of an important gene locus for tuberous sclerosis to a chromosome 16 marker

for polycystic kidney disease. *Nature Genet* 1992;2:37-41.

9. Braffman BH, Bilaniuk LT, Naidich TP, et al. MR imaging of tuberous sclerosis: pathogenesis of this phakomatosis, use of gadopentetate dimeglumine, and literature review. *Radiology* 1992;183:227-38.

10. Roach ES, Smith M, Huttenlocher P, Bhat M, Alcorn D, Hawley L. Diagnostic criteria of tuberous sclerosis complex. *J Child Neural* 1992;7:221-4.

11. Gomez MR. Tuberous sclerosis. New York: Raven Press, 1989.

12. Nixon JR, Houser OW, Gomez MR, Okazaki H. Cerebral tuberous sclerosis: MR imaging. *Radiology* 1989; 170:869-73.

13. Nixon JR, Okazaki H, Miller GM, Gomez MR. Cerebral tuberous sclerosis: postmortem magnetic resonance imaging and pathologic anatomy. *Mayo Clin Proc* 1989;64:305-11.

14. Altmann NR, Purser RK, Donovan Post MJ. Tuberous sclerosis: characteristics at CT and MR imaging. *Radiology* 1988;167:527-32.

15. Martin N, Debussche C, De Broucker T, Mompont D, Marsault C, Nahum H. Gadolinium- DTPA enhanced MR imaging in tuberous sclerosis. *Neuroradiology* 1990;31:492-7.

16. Wippold FJ 11, Baber WW, Gado M, Tobben PJ, Bartnicke BJ. Pre- and postcontrast MR studies in tuberous sclerosis. *J Comput Assist Tomogr* 1992; 161:69-72.

17. Inoue Y, Nakajima S, Fukuda T, et al. Magnetic resonance images of tuberous sclerosis. Further observations and clinical correlations. *Neuroradiology* 1988;30:379-84.

18. Berns DH, Masaryk TJ, Weisman B, Modic MT, Blaser SI. Tuberous sclerosis: increased MR detection using gradient echo techniques. *J Comput Assist Tomogr* 1989;13:896-8.

19. Abbruzzese A, Bianchi MC, Puglioli M, et al. Astrocitomi gigantocellulari nella sclerosi tuberosa. *Rivista Neuroradiol* 1992;5(suppi 1):11-116.

20. Morimoto K, Mogami H. Sequential CT study of subependymal giant-cell astrocytoma associated with tuberous sclerosis. *J Neurosurg* 1986;65: 874-7.

21. Fitz CR, Harwood-Nash DC, Thompson JR. Neuroradiology of tuberous sclerosis in children. *Radiology* 1974;110:635.

22. Russell DS, Rubinstein LJ. Pathology of tumors of the nervous system, 5th ed. Baltimore: Williams & Wilkins, 1989.

23. The European Chromosome 16 Consortium. Identification and characterization of the tuberous sclerosis gene on chromosome 16. *Cell* 1993;75: 1305-15.

24. Pont MS, Elster AD. Lesion of skin and brain: modern imaging of the neurocutaneous syndromes. *AJR* 1992;158:1193-7.

25. Metwally, MYM: Textbook of Neuroimaging, A CD-ROM publication, (Metwally, MYM editor) WEB-CD agency for electronic publication, version 9.4a October 2008