

# CASE OF THE WEEK

## PROFESSOR YASSER METWALLY

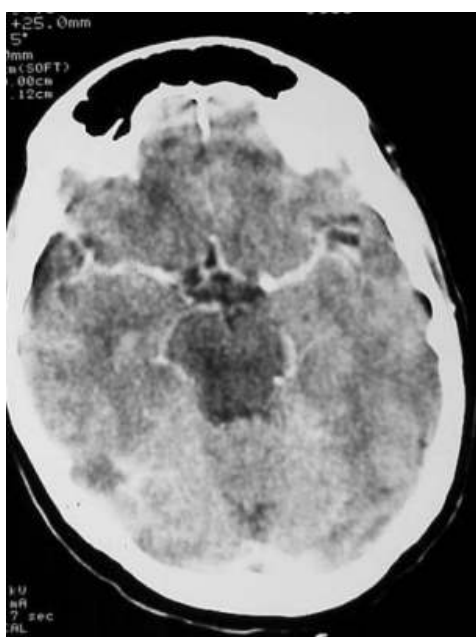
### CLINICAL PICTURE

#### CLINICAL PICTURE:

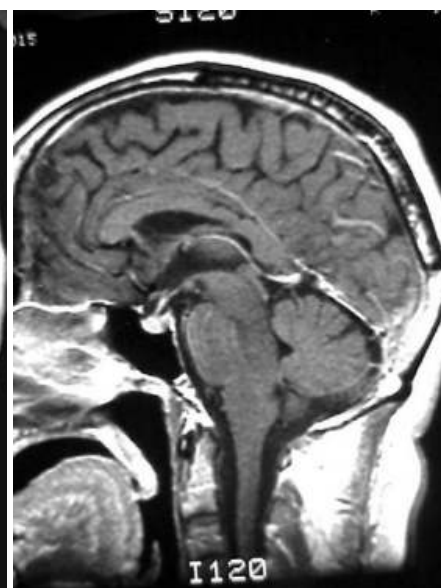
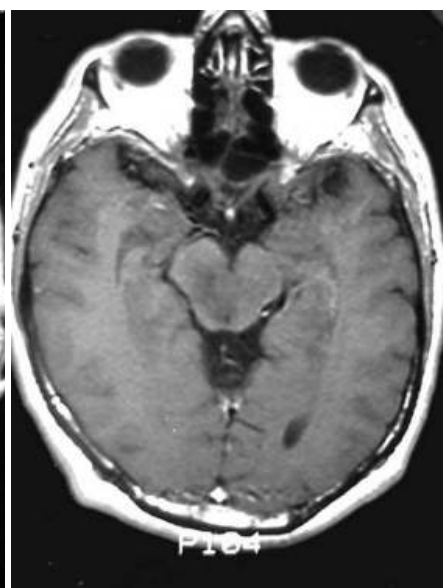
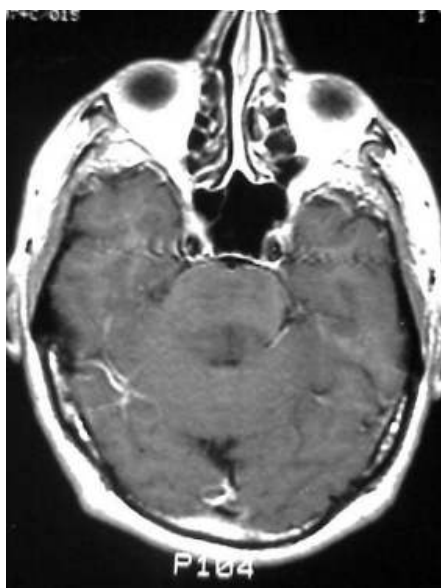
A 50 years old male patient presented clinically for the first time complaining of marked limitation of horizontal gaze bilaterally of around 4 years duration. The patient's brain CT scan showed a posteriorly located focal exophytic pontine glioma (Figure 1). At the time of the first presentation the patient refused any treatment or further investigation. Two years later the patient presented with a rapidly progressive bilateral weakness, sever headache, bilateral papilledema, vertigo and bilateral cerebellar manifestations. The patient was hospitalized and MRI examination of the brain was done (Figure 2,3,4,5). The patient suddenly died 2 days later.

### RADIOLOGICAL FINDINGS

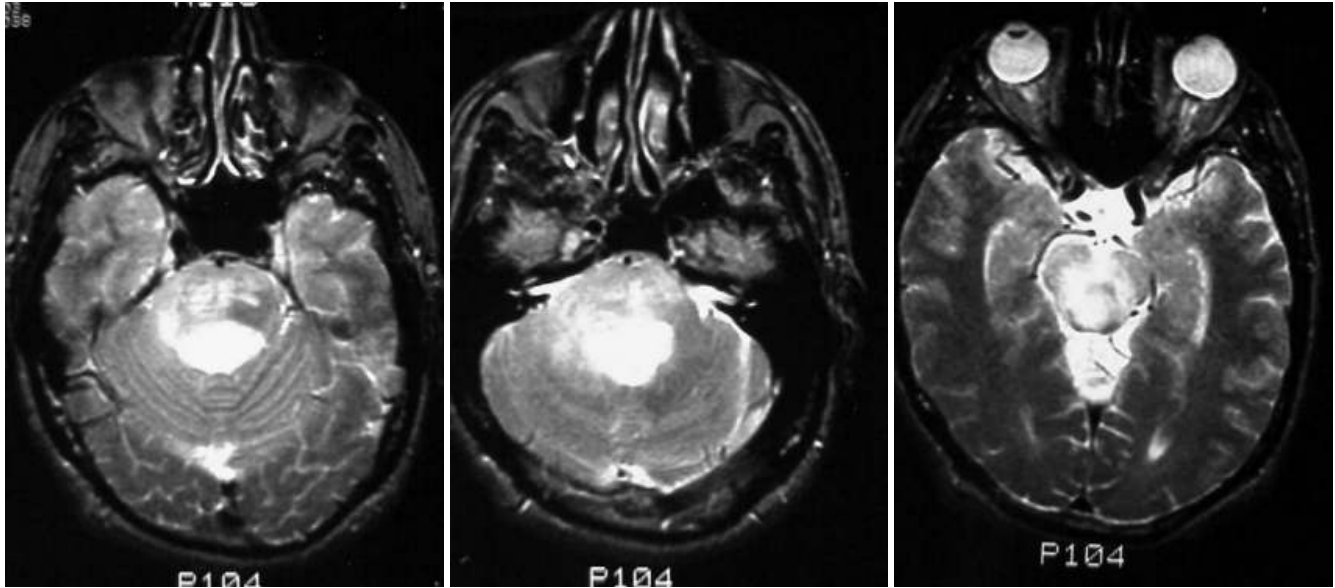
#### RADIOLOGICAL FINDINGS:



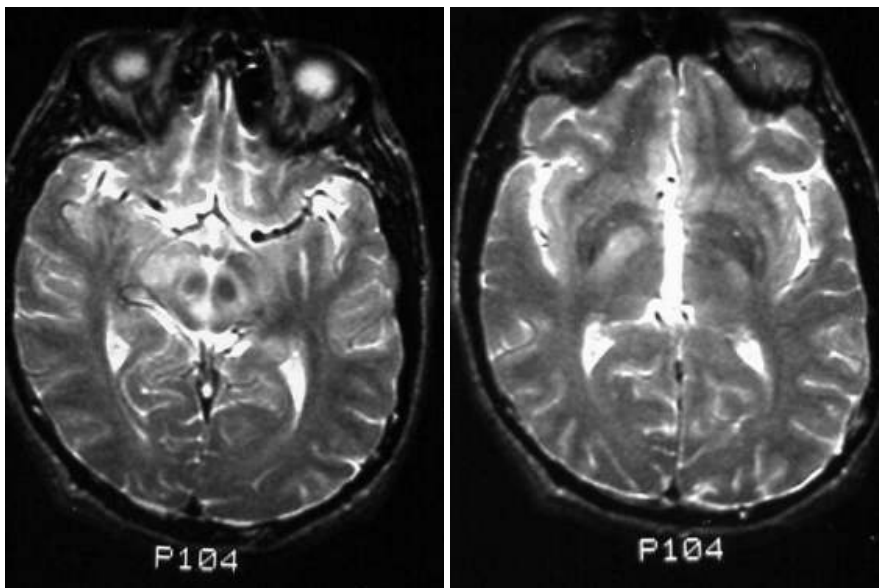
**Figure 1. Postcontrast CT scan image showing a dorsally exophytic focal pontine glioma. The 4th ventricle is compressed and pushed posteriorly. Notice absence of any significant contrast enhancement.**



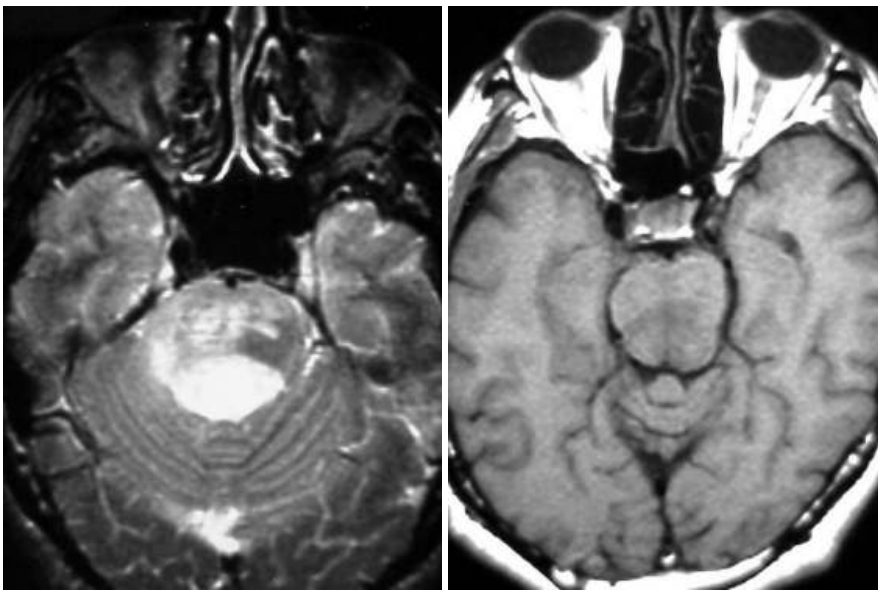
**Figure 2.** Postcontrast MRI T1 images showing a hypointense nonenhanced posteriorly located brain stem glioma. The tumor is located in the posterior parts of pons, with upward extension to the posterior parts of the midbrain and showed forward extension to the crus cerebri at the midbrain level. The cephalocaudal extension of the tumor is best depicted in the sagittal view in C and is seen as a hypointense broad band in the posterior parts of the brain stem. Mild punctate hypointensities are seen in the basis pontis and probably reflect forward extension of the tumour cells.



**Figure 3.** The tumor is seen hyperintense on the MRI T2 images. Notice the punctate hyperintensities that surround the the main bulk of the tumor. Most probably these punctate hyperintensities represent peritumoral satellitosis that occurred due to extension of the tumor cells along myelinated and non-myelinated pyramidal tract fibers.



**Figure 4.** The tumor showed upward extension to the crus cerebri and the posterior limbs of the internal capsule, more on the right side. This pattern of spread reflects extension of the tumor cells along myelinated and non-myelinated pyramidal tract fibers.



**Figure 5. MRI T2 (A) image and postcontrast MRI T1 image (B) at the pontine level. Notice the posteriorly located tumor and the peritumoral satellitosis.**

The patient history coupled with his radiological examination probably reflect the behavior and the natural history of diffuse astrocytoma. The tumor started focally as grade II diffuse pontine astrocytoma, and the condition of the patient remained stable for almost 5 years. However the patient's condition rapidly deteriorated, and probably that was due to tumor upgrading from grade II to glioblastoma multiforme. The tumor showed forward, upward, and downward extension along myelinated and non-myelinated pyramidal tract fibers. The observed peritumoral satellitosis is typical for diffuse astrocytomas.

**Box 1. Common pathological characteristics of diffuse astrocytomas**

- Diffuse astrocytomas are tumors predominantly composed of astrocytes. Unless otherwise indicated, the term usually applies to diffusely infiltrating neoplasms (WHO grades II through IV).
- Diffuse astrocytoma is unusual in the first decade of life and most commonly presents in older children or young adults up to the age of 40 to 45.
- All diffuse astrocytomas, particularly the diffusely infiltrating variety, have a tendency toward progression to more malignant forms. Diffuse astrocytomas have a peculiar tendency to change its grade over time into the next higher grade of malignancy and the condition is age dependant. A change in the grade of diffuse astrocytoma is more likely to occur in the older age group.
- Diffuse astrocytomas commonly start as grade II at a younger age group then gradually change its grade over time into the next higher grade until they ultimately dedifferentiate into glioblastomas (secondary glioblastoma multiforme), on the other hand, glioblastoma multiforme in older patients are usually primary-that is, they occur as glioblastoma multiforme from their inception, without progression from a lower- grade tumor.
- Diffuse astrocytomas appear to form a continuum of both biological and histological aggression. They vary from lesions with almost normal cytology (grade I and grade II astrocytomas) through intermediate stages (grade III, anaplastic astrocytomas) and up to the most aggressive of all human brain tumours (grade IV astrocytomas or glioblastoma multiforme).
- Diffuse astrocytoma often spreads widely through the brain but without destruction and also without interruption of normal function. Microscopically, tumor cells infiltrate between myelinated fibers in a nondestructive manner (perineuronal satellitosis). The local spread of diffuse astrocytomas (forming gliomatosis cerebri and butterfly gliomas) does not mean that the tumour grade is grade IV (glioblastoma multiforme), local spread can occur in grade II and grade III and in the author experience gliomatosis cerebri and butterfly gliomas are much more commonly seen in grade II astrocytomas and has not been encountered in grade III (anaplastic astrocytomas) and grade IV (glioblastoma multiforme). It takes a long time for a diffuse astrocytoma to cross the corpus callosum to the opposite hemisphere to form a butterfly glioma. Patients harbouring glioblastomas have a much shorter life span for their tumours to form butterfly gliomas, however cases were reported for glioblastomas forming butterfly tumours.
- These glioma cells migrate through the normal parenchyma, collect just below the pial margin (subpial spread), surround neurons and vessels (perineuronal and perivascular satellitosis), and migrate through the white matter tracks (intrafascicular spread). This invasive behavior of the individual cells may correspond to the neoplastic cell's reacquisition of primitive migratory behavior during central nervous system development. The ultimate result of this behavior is the spread of individual tumor cells diffusely over long distances and into regions of brain essential for survival of the patient. The extreme example of

this behavior is a condition referred to as gliomatosis cerebri, in which the entire brain is diffusely infiltrated by neoplastic cells with minimal or no central focal area of tumor per se. Furthermore, 25% of patients with GBM have multiple or multicentric GBMs at autopsy. Although GBMs can be visualized on MRI scans as mass lesions that enhance with contrast, the neoplastic cells extend far beyond the area of enhancement. Fig. 2 illustrates a typical result of "gross total resection" of a temporal lobe GBM followed 6 months later by recurrence at the surgical margin and elsewhere. Even with repeat surgeries for tumor recurrences, the patients die from tumor spread into vital regions of the brain.

- In practice considerable histological heterogeneity in astrocytic tumours is found ( i.e., low grade areas with Rosenthal fibers and calcification can be intermixed with with frankly malignant ones).<sup>29</sup>
- The differences in histologic features, potential for invasiveness, and extent of progression likely reflect genetic differences acquired during astrocytoma growth.
- Grade IV astrocytomas (glioblastoma multiforme) differ from diffuse astrocytoma grade II and grade III (anaplastic astrocytomas) in the presence of gross necrosis, and microscopically in the presence of vascular endothelial hyperplasia and tumour hemorrhage.

## **DIAGNOSIS:**

**DIAGNOSIS: DIFFUSE BRAIN STEM GLIOMA**

## **DISCUSSION**

### **DISCUSSION:**

Brainstem gliomas have historically been one of the most difficult pediatric cancers to treat. Tumors arising in the brainstem were once uniformly discounted as surgically unresectable lesions. Early neurosurgeons thought this location to be inoperable and fraught with disaster. The advent of computed tomography (CT), magnetic resonance imaging (MRI), and sophisticated neurophysiological monitoring techniques have significantly advanced the surgical treatment of these precarious lesions. Review: Brain-stem gliomas are now recognized as a heterogeneous group of tumors. They have been broadly classified into several categories depending upon the classification scheme. All these classification systems provide a framework to predict growth patterns, surgical resectability, and overall prognosis of these tumors. These systems allow the surgeon to obtain a better understanding of the distinction between low-grade tumors and diffuse inoperable tumor types.

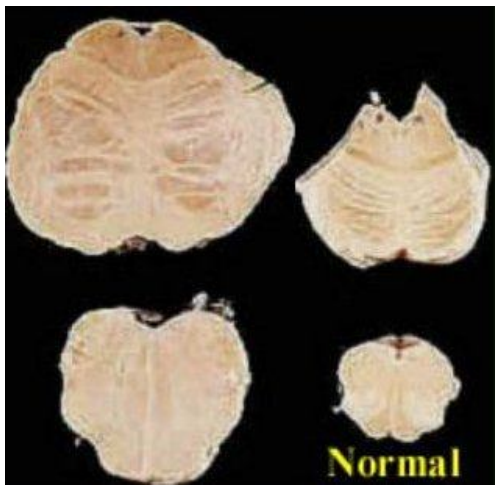The brainstem, or mesencephalon, is defined as the midbrain, pons, and medulla. Gliomas within the brain-stem constitute 10–20% of all pediatric CNS tumors. In the United States, there are approximately 150–300 annual cases [8, 63]. Brainstem gliomas can occur at any age, although they generally present in childhood, with the mean age of diagnosis of 7–9 years [15, 46]. There is no gender predilection.

In the era before modern imaging, all brainstem gliomas were regarded as a single pathological entity, and the prognosis was considered uniformly poor. In 1969, Matson summarized that “regardless of specific histology, brainstem gliomas must be classified as malignant tumors since their location in itself renders them inoperable” [50]. Pool was one of the first neurosurgeons to advocate surgery for certain brainstem tumors. He operated upon several children and reported a survival of 10–25 years (reported in [36]). In the early 1980s, several neurosurgeons began reporting favorable surgical outcomes for certain types of brainstem gliomas [10, 28, 30, 38, 62]. Classification systems were then introduced, which attempted to identify those tumors that benefited from surgery. These morphological systems evolved further with the advent of magnetic resonance imaging, thus helping to predict tumor behavior and determine the best management algorithm for these tumors.

- **Imaging and classification of brain stem glioma**

Magnetic resonance imaging (MRI) has emerged as the primary diagnostic modality for brainstem gliomas. MRI multiplanar images assist in the establishment of the tumor diagnosis, identification of tumor epicenter, and prediction of its biological behavior. Astrocytomas are the most common intrinsic tumor of the brainstem. Histologically, these tumors are fibrillary, in contrast to cerebellar astrocytomas, which are predominantly pilocytic. Other tumors that may arise in the brainstem include PNET (primitive neuroectodermal tumors), lymphomas, gangliogliomas, and oligodendrogliomas [23]. Lymphomas are distinguished by their uniform enhancement after gadolinium administration. Although ependymomas are extra-axial, they can resemble an intrinsic tumor of the brainstem since they may cause brainstem compression or appear to insinuate into the brainstem by their lateral extension out the foramen of Luschka. Ependymomas can also originate as cervicomedullary lesions. Non-neoplastic lesions such as hemangioblastomas, cavernous malformations, tuberculomas, and epidermoids have also been reported to arise within the brainstem. Additional imaging studies such as angiography, MRI spectroscopy or diffusion-weighted MRI sequences may be required if the diagnosis is uncertain [25, 51]. These imaging sequences have supplanted the need for stereotactic biopsy for certain brainstem gliomas [7,70].





**Figure 1. Brain stem primary diffuse astrocytoma (grade II) causing diffuse enlargement and expansion of the brain stem with maximal pontine involvement.**

Many classification schemes have been devised for brainstem tumors [70] (Table 1). The earliest categorizations relied on computed tomography (CT) and surgical observations; however, the more recent schemes include MRI sequences. All these systems categorize the tumor by epicenter (diffuse or focal) or imaging characteristics. The simplest classification divides these tumors into two groups, either focal or diffuse regardless of tumor epicenter. The more complex schemes subdivide these tumors by location, focality, presence of hydrocephalus or hemorrhage, and growth pattern.

**Table 1. Classifications of brain stem glioma**

| Author | Classification system  | System based on  |
|--------|--|--|
| [27]   | Intrinsic<br>Diffuse<br>Focal<br>Cervicomedullary<br>Exophytic<br>Anterolateral into cerebellopontine angle<br>Posterolateral into brachium pontis<br>Posterior into fourth ventricle<br>Disseminated<br>Positive cytology<br>Positive myelography   | Computed tomography  |
| [28]   | Diffuse<br>Focal<br>Circumscribed mass less than 2 cm, no edema<br>Cervicomedullary  | Computed tomography, magnetic resonance imaging and surgical observation |
| [62]   | Group I—dorsal exophytic glioma<br>Group IIa—intrinsic brainstem tumors<br>Hypodense, no enhancement<br>Group IIb—intrinsic brainstem tumors<br>Hyperdense, contrast enhancing, exophytic<br>Group III—focal cystic tumor with contrast enhancement<br>Group IV—focal intrinsic isodense, contrast enhancing | Computed tomography  |
| [12]   | Location<br>Midbrain, pons, medulla<br>Focality<br>Diffuse or focal<br>Direction and extent of tumor growth<br>Degree of brainstem enlargement<br>Exophytic growth<br>Hemorrhage or necrosis<br>Evidence of hydrocephalus  | Magnetic resonance imaging   |
| [5]    | Focal<br>Midbrain, pons (dorsal exophytic pontine glioma), medulla<br>Diffuse  | Magnetic resonance imaging   |
| [33]   | Midbrain<br>Diffuse, focal, tectal<br>Pons<br>Diffuse, focal<br>Medulla<br>Diffuse, focal, dorsal exophytic  | Magnetic resonance imaging   |
| [23]   | Type I—intrinsic tumor, diffuse, hypodense on CT, low intensity in T1-weighted images, with no significant enhancement<br>Type II—intrinsic and focal tumor, which may be solid or cystic<br>Type III—exophytic tumor, either dorsally or laterally<br>Type IV—cervicomedullary tumor                        | Computed tomography and magnetic resonance imaging                       |

○ Diffuse brainstem gliomas

Diffuse gliomas are the most commonly encountered tumor of the brainstem accounting for 58–75% of all tumors [5, 30]. On T1-weighted MRI scans, they appear hypointense with indistinct margins, reflecting the infiltrative nature of these high-grade

lesions (Fig. 1). Diffuse gliomas of the brainstem are generally greater than 2 cm in size at time of presentation. They are characterized by diffuse infiltration and swelling (or hypertrophy) of the brainstem. The epicenter of the lesion is usually the pons; however, rostral or caudal tumor extension is not unusual. These diffuse gliomas are distinguished from focal tumors by their indiscrete hyperintensity on T2-weighted imaging. Gadolinium enhancement can be variable and has no prognostic implication [33]. These diffuse gliomas are typically malignant fibrillary astrocytomas (Grade III or IV).

- Focal tumors

Focal tumors are defined as demarcated lesions of the brainstem found in the midbrain, pons or medulla. These focal tumors may be solid or cystic and they always have clear, distinct borders on MRI (Fig. 2). The tumor size and characteristics are similar on both T1 and T2 sequences because of the relative lack of infiltration and edema. Tumor enhancement following gadolinium administration may be variable, but uniform enhancement is suggestive of a juvenile pilocytic astrocytoma. These focal tumors are mostly histologically benign (Grade I or II) lesions; however, anaplastic gangliogliomas and PNETs have been reported [1].

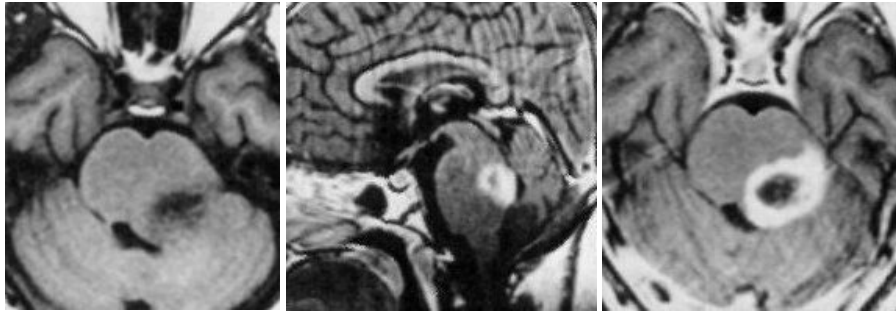


Figure 2. MRI T1 precontrast (A) postcontrast (B,C) showing posterior pontine glioblastoma multiforme with necrosis and ring enhancement. The existence of necrosis or contrast enhancement should shift the diffuse astrocytoma grade to grade IV

- Exophytic tumors

Dorsally exophytic brainstem gliomas are a group of tumors that arise from the subependymal glial tissue (Fig. 3). The bulk of the tumor resides within the fourth ventricle, which accounts for the relatively late onset of symptoms. MRI reveals a well-demarcated lesion with similar T1-hypointensity and T2-hyperintensity signal characteristics.

Histologically, these tumors are almost always low-grade gliomas. They tend to grow along paths of least resistance (into the fourth ventricle and into cisterns) rather than infiltrate the brainstem [39]. Most of these exophytic tumors will enhance with gadolinium, and can be difficult to distinguish from ependymomas or choroid plexus papillomas [14]. In general, exophytic tumors that grow laterally and ventrally into the brainstem are higher-grade tumors than those exophytic tumors that project dorsally into the fourth ventricle.

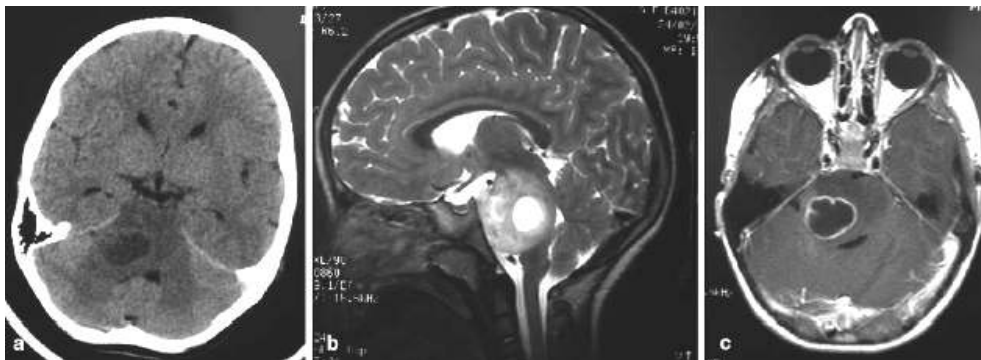
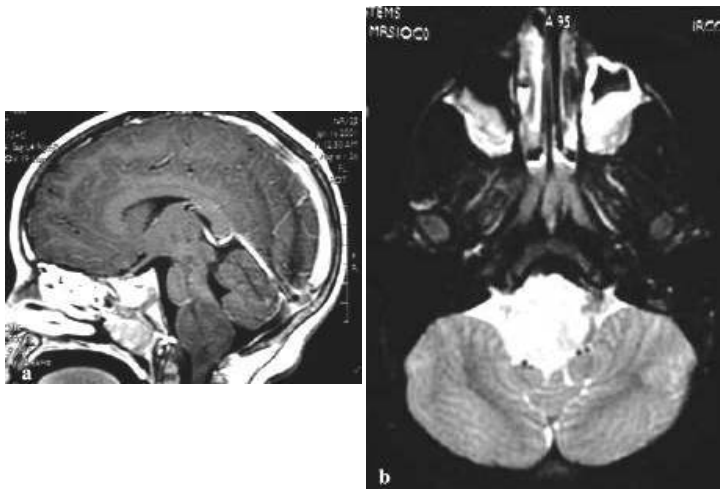
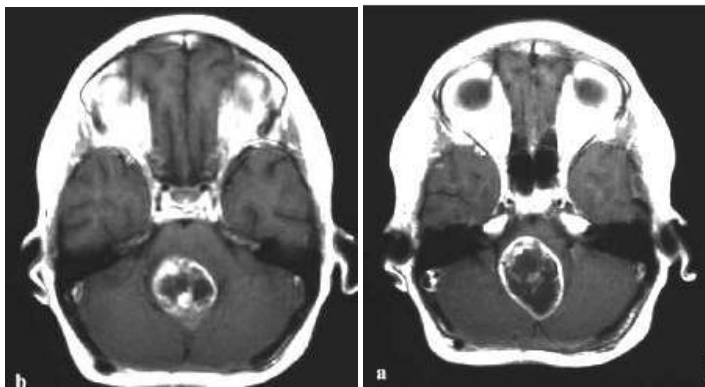


Figure. 3 A, Diffuse pontine glioma. a CT scan demonstrates the signal change within the pons associated with a necrotic center. B Sagittal T2-weighted MRI scan demonstrates an enlarged pons with a necrotic area. C, Axial T1-weighted image with gadolinium demonstrates the enhancing tumor with surrounding hypointense signal within the pons.



**Figure 4. Focal tumor. A, Sagittal T1-weighted MRI with gado-linim demonstrates a minimally enhancing tumor within the medulla. B, Axial T2-weighted image demonstrates the location within the medulla. Histology confirmed a ganglioglioma**

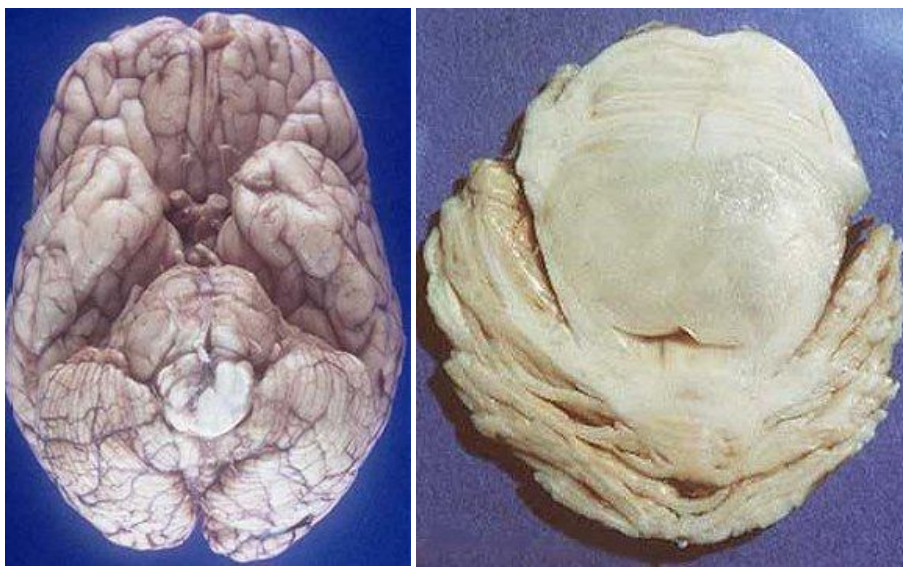


**Figure 5. A,B Dorsal exophytic glioma. a, b T1-weighted axial MRI with gadolinium of an exophytic tumor within the fourth ventricle. Histology confirmed a juvenile pilocytic astrocytoma**

- Cervicomedullary tumors

Cervicomedullary brainstem gliomas are similar to intramedullary spinal cord gliomas. The epicenter of these tumors may be either in the medulla or cervical spinal cord. On MRI, these tumors show mixed low and intermediate signal intensity within the solid part of the tumor. MRI assists in delineating the rostral and caudal pole of these tumors, as well as identifying any associated syrinx or cysts.

The majority of these tumors are benign low-grade astrocytomas, and they demonstrate distinct growth patterns [31, 39]. These tumors have almost no infiltrative capacity and as a consequence their growth is limited rostrally by the decussating white matter tracts of the corticospinal tract and medial lemniscus, which act as a barrier for further rostral growth. Tumors that arise within the medulla are confined by the decussating fibers and expand within the medulla, pushing the motor tracts and nuclei to the periphery. Thus, these low-grade tumors may appear exophytic and displace the medulla rostrally, while the upper cervical cord appears expanded. Only high-grade tumors with an infiltrative capacity grow rostrally into the brainstem.



**Figure 6. Brain stem primary diffuse astrocytoma (grade II) causing diffuse enlargement and expansion of the brain stem with maximal pontine involvement. The 4th ventricle in compressed and displaced posteriorly. The basilar artery is partially surrounded by the brain stem tumour.**

**Table 2. Types of brain stem gliomas**

| Tumor                            | Comment  |
|----------------------------------|--|
| <b>Diffuse brainstem gliomas</b> | Diffuse gliomas are the most commonly encountered tumor of the brainstem accounting for 58–75% of all tumors [5, 30]. On T1-weighted MRI scans, they appear hypointense with indistinct margins, reflecting the infiltrative nature of these high-grade lesions (Fig. 1). Diffuse gliomas of the brainstem are generally greater than 2 cm in size at time of presentation. They are characterized by diffuse infiltration and swelling (or hypertrophy) of the brainstem. The epicenter of the lesion is usually the pons; however, rostral or caudal tumor extension is not unusual.   |
| <b>Focal tumors</b>              | Focal tumors are defined as demarcated lesions of the brainstem found in the midbrain, pons or medulla. These focal tumors may be solid or cystic and they always have clear, distinct borders on MRI (Fig. 2). The tumor size and characteristics are similar on both T1 and T2 sequences because of the relative lack of infiltration and edema. Tumor enhancement following gadolinium administration may be variable, but uniform enhancement is suggestive of a juvenile pilocytic astrocytoma. These focal tumors are mostly histologically benign (Grade I or II) lesions; however, anaplastic gangliogliomas and PNETs have been reported [1]. |
| <b>Exophytic tumors</b>          | Dorsally exophytic brainstem gliomas are a group of tumors that arise from the subependymal glial tissue (Fig. 3). The bulk of the tumor resides within the fourth ventricle, which accounts for the relatively late onset of symptoms. MRI reveals a well-demarcated lesion with similar T1-hypointensity and T2-hyperintensity signal characteristics.   |
| <b>Focal tectal gliomas</b>      | Focal tectal gliomas represent the third type of adult brainstem glioma and constitute a small subgroup (8%) that also exists in children. The clinical picture is dominated by hydrocephalus. (69)  |
| <b>Cervicomedullary tumors</b>   | Cervicomedullary brainstem gliomas are similar to intramedullary spinal cord gliomas. The epicenter of these tumors may be either in the medulla or cervical spinal cord. On MRI, these tumors show mixed low and intermediate signal intensity within the solid part of the tumor. MRI assists in delineating the rostral and caudal pole of these tumors, as well as identifying any associated syrinx or cysts.   |

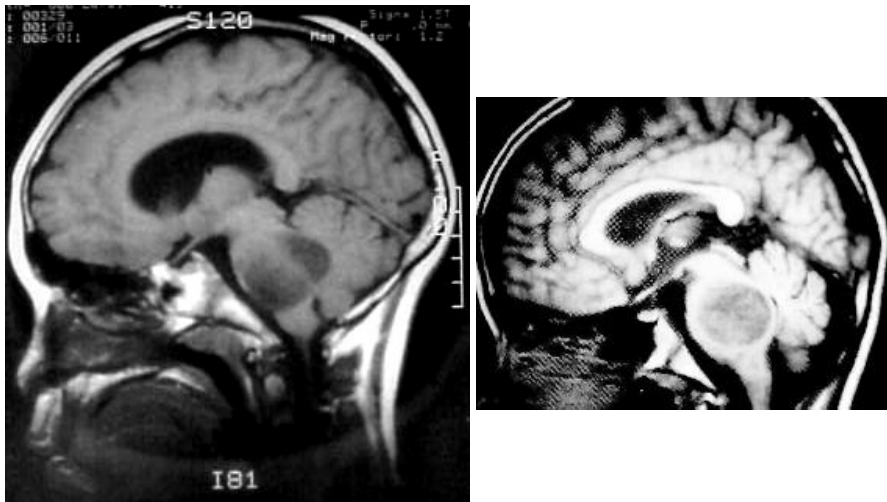
- **Management of brain stem glioma**

The clinical history and presentation are important in the establishment of the tumor histology and overall prognosis. A careful history is obtained from both the child and a parent. This is important since, often, subtle changes may be unreported if both individuals are not interviewed. For example, old pictures may be necessary to date the onset of cranial neuropathies. Declining school performance, especially related to visual disturbances or symptoms of hydrocephalus, may be the only presenting signs. A detailed history should include previous upper respiratory tract infections, pneumonias, or changes in voice [4]. The length of the prodrome or symptoms is an indication of the tumor histology.

Malignant lesions invariably have a rapidly progressive course. Children with diffuse brainstem gliomas will often present acutely with multiple cranial nerve signs, ataxia, long tract signs, and cerebellar signs. Diffuse gliomas are unfortunately the most common brainstem lesion, and regrettably, this tumor portends the worst prognosis among the brainstem gliomas. Most children die within 18 months of diagnosis, which is similar to the clinical course for glioblastoma multiforme [6, 46]. There is no role for radical surgery or biopsy since stereotactic biopsy does not change the management strategy [7]. A biopsy should be reserved for indeterminate lesions on MRI accompanied by an unusual presentation or when mandated by a study



protocol. Diffuse brainstem tumors, which are associated with neurofibromatosis need further investigation, because they tend to have a more favorable prognosis. These NF-1 brainstem tumors typically have an indolent course, reminiscent of their astrocytic counterparts in the hypothalamic/optic chiasm region [49, 54]. Careful clinical examination for the stigmata of neurofibromatosis and family history should help in the identification of these lesions. Magnetic resonance spectroscopy has also been shown to be useful in distinguishing diffuse lesions in NF-1 patients [20]. Radiation and/or chemotherapy are the current mainstays of treatment for diffuse brainstem gliomas [9].



**Figure 7. MRI postcontrast T1 images of primary diffuse astrocytoma in two patients causing diffuse enlargement of the brain stem with maximal pontine involvement. The brain stem tumours are hypointense with absence of postcontrast enhancement. Histopathological specimen showed diffuse astrocytomas grade II in both patients mixed with anaplastic (grade III) areas in (B). The 4th ventricle is compressed and displaced posteriorly.**

In contrast, focal tumors are generally low-grade gliomas, and have a longer prodrome (months to years) before diagnosis when compared with the shorter period (weeks to months) for diffuse gliomas. The location of the focal tumor along the brainstem axis influences the clinical presentation. In general, upper brainstem tumors tend to present with hydrocephalus, oculomotor dysfunction and/or cerebellar findings, whereas lower brainstem tumors present with lower cranial nerve deficits and long tract findings.

Midbrain gliomas of the tectum behave as very low-grade lesions [17]. Focal tumors of the tectum (tectal gliomas) begin to cause significant neurological symptoms when they enlarge and compress the aqueduct of Sylvius thereby producing obstructive hydrocephalus. Tegmental tumors can present with hydrocephalus and oculomotor paresis with or without associated long tract findings. Focal pontine gliomas generally have a poorer prognosis while focal tumors of the medulla are intermediate. Pontine lesions cause facial paresis, hearing loss or long tract findings. Concern should be raised when a child presents with a localized focal nonenhancing tumor with rapid progression of symptoms. Atypical tumors that present at a very young age and with leptomeningeal dissemination may be primitive neuroectodermal tumors (PNET) [68]. An excisional biopsy should be considered in this situation since treatment protocols for PNETs differ from those for brainstem gliomas.

Tumors of the medulla present with lower cranial nerve deficits, which manifest as changes in voice, swallowing difficulty or pneumonias due to microaspirations. Although these focal lesions are not infiltrative, they can carry a high surgical morbidity [2]. Preoperative medullary dysfunction warns of postoperative complications specifically in patients demonstrating frequent preoperative upper respiratory tract infections, preoperative pneumonia or alteration in voice [4].

Dorsally exophytic tumors may be regarded as a type of focal tumor (Table 3). There is usually a protracted yet progressive clinical course with symptoms due to either direct compression of the underlying brainstem or to elevated intracranial pressure from obstruction of CSF pathways. Young children may present with failure to thrive due to intractable vomiting. Older children may exhibit headache and ataxia. Papilledema and torticollis are common presenting signs, resulting from increased intracranial pressure and chronic tonsillar herniation. The majority of dorsally exophytic tumors can be managed successfully with subtotal resection, and if necessary, CSF diversion [52].

**Table 3. Summary of surgically-treated dorsal exophytic brainstem tumors. LGA low grade astrocytoma, JPA juvenile pilocytic astrocytoma**

| Author  | Patients | Histology  | Surgery                    | Adjuvant Therapy | Outcome                       | Progression |
|---|----------|--|----------------------------|------------------|-------------------------------|-------------|
| [52]  | 18       | 16 LGA grade I or II<br>1 astrocytoma grade III<br>1 ganglioglioma | Near total                 | 2 patients       | 17 alive (median, 113 months) | 4 patients  |
| [44]  | 12       | 11 JPA<br>1 LGA  | 6 near total<br>6 subtotal | 2                | 11 alive (median, 26 months)  | 3           |
| [33]  | 10       | N/A  | N/A                        | N/A              | 7 alive (mean, 35 months)     | N/A         |
| Near total >90% resection, subtotal >50% but <90% |          |  |                            |                  |                               |             |

Cervicomedullary brainstem gliomas are also associated with an indolent course. The presentation of these tumors is dependent on the epicenter of the lesion. Two presenting syndromes, a medullary and a cervical cord syndrome, have been described. Medullary dysfunction may manifest as failure to thrive due to nausea, vomiting, or dysphagia, upper respiratory tract infection, dysarthria, and sleep apnea. The cervical cord dysfunction will manifest as chronic neck pain and progressive cervical myelopathy with weakness and spasticity. Good long-term outcomes have been achieved with radical resection (Table 4) [13, 29, 56, 66].

**Table 4. Summary of surgically-treated cervicomedullary tumors. LGA low grade astrocytoma, JPA juvenile pilocytic astrocytoma. Near total >90% resection, subtotal >50% but <90%, partial <50%**

| Author | Patients | Histology  | Surgery  | Adjuvant therapy | Outcome                      | Progression   |
|--------|----------|--|--|------------------|------------------------------|---|
| [29]   | 20       | 11 LGA grade I or II<br>4 astrocytoma grade III<br>3 ganglioglioma<br>2 ependymoma                   | N/A  | 4 patients       | 16 alive (median, 24 months) | 4/4 of high grade tumors<br>1/16 of low grade tumors  |
| [56]   | 17       | 10 LGA<br>6 ganglioglioma<br>1 mixed astrocytoma   | 2 gross total<br>15 subtotal                               | 2                | 15 alive (median, 48 months) | 6 patients  |
| [13]   | 4        | 3 JPA<br>1 ependymoma  | N/A  | N/A              | N/A                          | N/A   |
| [66]   | 39       | 15 LGA<br>9 ependymoma<br>7 ganglioglioma<br>3 JPA<br>anaplastic<br>3 astrocytoma<br>2 mixed gliomas | 12 gross total<br>7 near total<br>15 subtotal<br>5 partial | None             | 39 alive (mean, 48 months)   | 3/4 of high grade tumors<br>12/35 of low grade tumors |

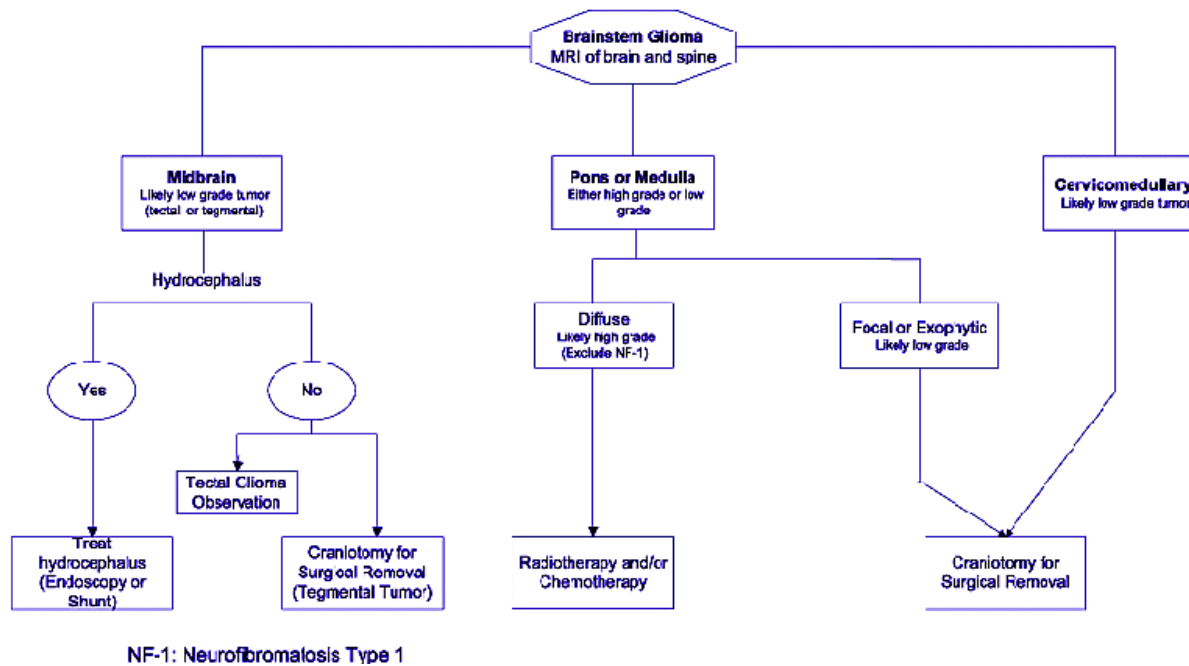
#### o Surgical treatment

Careful patient selection is one of the underlying principles behind successful brainstem tumor surgery. The categorization of brainstem tumors has helped to predict growth patterns and identify surgically treatable lesions. Surgery for diffuse brainstem gliomas is generally not indicated. This section will address open surgical treatment of focal, dorsally exophytic, and cervicomedullary tumors. Certain focal lesions, particularly tectal gliomas, have an indolent natural history and do not generally require open surgical management. Tectal gliomas are managed by treatment of symptomatic obstructive hydrocephalus using endoscopic third ventriculostomy or shunting. The advantages of endoscopic third ventriculostomy include avoidance of an implant device and potential for a minimally invasive biopsy of the tumor mass. Early surgery as a first line intervention have been favored, particularly before significant progression of symptoms and before other treatments such as radiotherapy or chemotherapy are administered. The goal of surgery is to decrease the tumor burden without incurring significant neurological complications. This goal can often be accomplished without gross total resection; however, there are significant potential morbidities, including tracheostomy and feeding gastrostomy.

Intraoperative neurophysiological mapping and monitoring is recommended for all brainstem cases [26, 50]. While MRI may provide accurate localization of the tumor, it does not provide information regarding the function of surrounding normal tissues. Although safe entry zones (suprafacial/infracial triangles, intercollicular midline incision) have been described, intrinsic tumors of the brainstem often distort the normal anatomy, thus obscuring normal landmarks [50]. Neurophysiological mapping overcomes this limitation by identifying displaced structures, and thus avoiding brainstem injury. In addition, continuous monitoring of standard evoked potentials (motor and sensory), and cranial nerve reflex circuits can be used to give real time feedback as to the integrity of the brainstem during tumor resection [26].

Special microsurgical equipment, which have greatly enhanced the operative technique, include the operating microscope, plated bayonets forceps [32], Nd:YAG contact laser [41], and the cavitron ultrasonic aspirator (CUSA) [24, 40]. The current CUSA models are equipped with smaller handsets that allow them to be safely used within the confined limits of the brainstem. The contact Nd:YAG laser provides precision cutting coupled with coagulation of adjacent tissues. It can be used for tumor resection with minimal injury to the surrounding brain-stem cranial nerve nuclei. The laser does not interfere with the intraoperative neurophysiological monitoring, which is critical for surgery.

Figure 8. Management strategy for brainstem tumors



Surgical approaches to the brainstem are predominantly through the posterior fossa. The prone position provides excellent exposure of the entire brainstem except for upper midbrain tumors. Some surgeons prefer the sitting position [19]; however, the prone position reduces the risk of venous air embolism and pneumocephalus. In addition, the prone position provides a surgical field that is readily accessible to both the surgeon and assistant. The surgeon's arms are not elevated throughout the case and there is less general fatigue. Proper positioning, especially with regard to neck flexion and shoulder placement is important for adequate visualization of the anticipated lesion. There are many different skull base approaches available depending on the location of the tumor.

#### ■ Midbrain

Although most tumors of the upper midbrain are managed conservatively with CSF diversion, some tumors in this area progress and require open surgery. The dorsal midbrain can be exposed by the infratentorial–supracerebellar approach first described by Kraus and then popularized by Stein [59]. A craniotomy is fashioned to incorporate the transverse sinus. The cerebellum and vermis may then be retracted caudally to expose the dorsal aspect of the mesencephalon. This approach allows direct access to the midbrain without intervening brain tissue [11]. The deep venous drainage system, including the vein of Galen and internal cerebral veins, is generally above the surgical field and thus easily avoided. Lesions on the ventral medial aspect of the midbrain near the interpeduncular cistern are reached by a standard pterional approach. Ventral lateral masses of the midbrain may be reached by a subtemporal approach and usually involve splitting the tentorial incisura. It should be kept in mind, however, that the subtemporal approach has the disadvantage of potentially requiring prolonged retraction of the temporal lobe.

#### ■ Pons

For dorsally situated tumors of the pons or medulla, a midline suboccipital craniotomy is the most common approach. A craniotomy is generally preferred over a craniectomy especially in children [37]. Replacement of the bone flap provides additional protection, and allows better restoration of anatomical tissue planes, which becomes important in the unfortunate patient who may require multiple resections [45]. The telovelar approach provides adequate exposure to all dorsally exophytic tumors [55]. Excessive traction on the cerebellar hemispheres and dissection on the vermis should be avoided because of the risk of cerebellar mutism and pseudobulbar symptoms [53, 60, 67]. For focal intrinsic tumors, the resection begins after the floor of the fourth ventricle has been identified and mapped for safe points of entry. If distortion and discoloration of the floor are insufficient to localize the tumor, ultrasound can be used to determine where the tumor is closest to the floor.

Tumors of the ventral lateral aspect of the pons extending into the cerebellopontine angle may be reached with the lateral retrosigmoid approach. The asterion, which is formed by the lambdoid and temporal squamous sutures, is a useful landmark for planning the bony removal. The junction of the transverse and sigmoid sinuses is identified and used as a guide for dural opening. The tumor may be debulked with special attention to the location of the tracts of cranial nerves 5, 7, and 8, and, if involving the medulla, 9 and 10.

#### ■ Medulla and upper cervical spine

For intrinsic tumors of the medulla, a suboccipital craniotomy with removal of the dorsal lateral rim of the foramen magnum enhances the exposure of the bulging medulla. A cervical laminotomy or laminectomy is performed for tumors that extend

caudally into the cervical region. This should encompass the most caudal aspects of the tumor. The medulla is typically displaced superiorly as the tumor grows posterior to the obex. The tumor is quite superficial here; almost invariably subpial in location. The posterior inferior cerebellar arteries, which may be displaced, must be preserved to avoid cerebellar or brainstem infarcts. However, superficial pial vessels may be taken if obstructing the intramedullary component of the tumor.

- **Surgical considerations**

One of the early considerations for a brainstem focal tumor is to determine a safe entry point. Cystic focal tumors are generally easier to treat than solid lesions because they can be more easily entered and their walls inspected for tumor nodules without having to manipulate the surrounding tissue. Discoloration and loss of surface markings may be used as rough guides in mapping the floor of the fourth ventricle when searching for safe entry zones. The contact laser is used to perform the initial incision or myelotomy into the brainstem. This process eliminates the superficial feeding blood vessels and initiates tumor retraction. The lack of tumor demarcation from the surrounding brain often hinders complete resection. The neurosurgeon must remember that complete resection is prohibitive in this situation due to the high probability of postoperative morbidity. It should also be kept in mind that a radical or gross total resection can be equally successful. It is important to minimize retraction of surrounding neural tissue during the resection. The tumor is removed in a piecemeal fashion using a combination of suction-aspiration and the CUSA. Tumor debulking and dissection is achieved by working from the insideout direction. The Nd:YAG laser is sometimes helpful in removing small amounts of tumor at the margins or in tight confines. Cautery is to be avoided at the margins of the tumor as this will frequently result in injury to the surrounding functional tissue. Mapping of the walls of the resection cavity can be performed in an attempt to define tumor margins. Tissue specimens are always sent early for frozen section analysis. If the histology is identified as a high-grade tumor the operation is stopped because there has been no proven long-term benefit to surgical debulking of these aggressive lesions.

Dorsally exophytic tumors were the first type of brainstem gliomas to be routinely treated with radical surgery [33, 44, 52]. Most of the dissection and removal is accomplished outside of the brainstem since these tumors are predominantly situated in the fourth ventricle. These tumors are approached via a standard midline suboccipital approach. One of the most important aspects of the case is to progressively debulk the tumor while keeping the floor of the fourth ventricle in view as it is important not to enter the brainstem parenchyma. Cranial nerves 6 and 7 are especially susceptible to injury because their nuclei and/or tracks are close to the dorsal surface of the stem and the floor of the fourth ventricle. The area immediately around the obex and calamus scriptorius should be avoided because of possible injury to cranial nuclei for 10 and 12. When these structures are injured, patients develop impaired swallowing, loss of coughing reflex, and dysphonia. A subtotal resection with preservation of neurological function is the goal of the surgery.

Patients with cervicomedullary tumors also benefit from radical surgical treatment [13, 29, 56, 66]. A midline suboccipital craniotomy and cervical laminectomies provide the necessary exposures. Excessive removal of cervical lamina is avoided to prevent the development of spinal deformity. Osteoplastic laminectomy is considered if a multilevel cervical laminectomy is required [3]. Although this technique may not always prevent deformity, there is reossification of the bone segments, which can avoid the cosmetic deformity frequently seen with multilevel laminectomies. The location of the tumor and any associated cysts is confirmed by ultrasound. A midline myelotomy is performed with the Nd:YAG laser in order to avoid injury to the posterior columns. The myelotomy is first directed over any associated rostral or caudal cyst and then extended over the solid part of the tumor. Identification of the dorsal root entry zones bilaterally is necessary to properly find the midline. The tumor's dorsal surface is exposed and the tumor entered, with a piecemeal removal performed from the center outwards. This is done with the CUSA and/or contact laser using the same techniques described earlier for intrinsic focal brainstem tumors. Meticulous care in the closure is important for the avoidance of a CSF leak—a complication not uncommon when operating on these tumors.

- **Complications**

Neurologically, the patient's preoperative symptoms may be transiently or permanently worsened after surgery. For this reason special care needs to be taken during the postoperative period [65].

If a significant amount of the medulla is involved with the tumor, the patient is left intubated for at least 48–72 h after surgery. This is critically important for any patient with evidence of dysfunction in the medulla's cranial nerves. Impaired central respiratory function may result in carbon dioxide retention and progressive hypoxia leading to respiratory arrest and further neurological injury, which is usually permanent [2]. The patient is weaned from the ventilator after 24 consecutive hours of stable respiratory drive.

Cranial nerve deficits are variable and dependent on the surgical approach. Surgery within the pons can result in transient diplopia due to internuclear ophthalmoplegia. This complication is often transient and improves. For persistent diplopia, ophthalmologic treatment with special eyeglass prisms may be necessary. Facial palsy can be devastating not only cosmetically but also functionally with regard to corneal injury. Several plastic surgical procedures have been developed to restore facial tone and protect the eye from corneal abrasions and keratitis [57]. Damage to the lower cranial nerves (9–12) can result in severe dysphagia, vocal cord paralysis, and loss of gag and cough reflexes. As a result, these patients are at risk of subclinical microaspirations, which may lead to recurrent and debilitating pneumonias. Formal swallowing evaluations are performed for all patients with questionable function before advancement of diet.

- **Oncologic outcome**

The neurosurgeon should be aware of all the available protocols for brainstem gliomas. Radiation therapy has provided only



marginal gains in the overall prognosis for diffuse high-grade tumors. Standard irradiation treatment combined with new chemotherapy protocols has had some mixed results (Table 5) [16, 21, 34, 35, 42, 43, 64]. These issues are reviewed elsewhere [9]. There are new therapeutic options under current investigation including convection-enhanced delivery [47, 58], slow-flow delivery [22, 61], radiosensitizing agents, and hyperbaric and interstitial radiotherapy.

| Chemotherapy                  | Radiotherapy (Gy) | Patients | Outcome                 |
|-------------------------------|-------------------|----------|-------------------------|
| 5-FU, CCNU, HDU, misonidazole | 55                | 28       | MST 44 weeks            |
| COPP                          | 56                | 7        | Progression at 4 months |
| VCR, CCNU, prednisone         | 50–60             | 35 RT    | MST 9 months both arms  |
|                               |                   | 39 chemo |                         |
| VP-16, trofosfamide           | 54                | 18       | PFS 179 days            |
| Carboplatin, VP-16            | 70.2              | 9        | 8/9 died at 44 weeks    |

**Table 5. Summary of several chemotherapy and radiotherapy protocols for diffuse pontine gliomas. MST mean survival time, PFS progression-free survival**

There have been minimal improvements in the long-term survival of patients with low-grade brainstem gliomas directly attributed to adjuvant therapy. Given the significant advances in surgical management of brainstem lesions and the decrease in surgical morbidity, second surgery has become a viable option [18]. Indications for second surgery have included:

1. Delayed, recurrent growth in either the solid or cystic component of the tumor resulting in new symptoms
2. Reexploration after the initial resection was halted prematurely due to transient intraoperative injury confirmed by monitoring

The goal of the reoperation is identical to that of the first operation, i.e., sufficient debulking of the tumor so as to lessen symptoms without causing progression in neurologic deficits.

- **Conclusion**

Brainstem gliomas are a heterogenous group of tumors that may be diffuse, focal, dorsally exophytic, or cervi-comedullary. These classification schemes help in predicting growth patterns and identifying surgically treatable lesions. Almost all diffuse tumors are malignant and nonresectable. The majority of other tumors are focal low-grade neoplasms that are amenable to surgery and long-term survival.

## SUMMARY

### SUMMARY

Adult brainstem gliomas are different from the childhood subtypes. Overall, brainstem gliomas are less aggressive in adults than in children. However, survival merely reflects the course of the most frequent subtype of tumours.

- **Diffuse intrinsic low-grade brainstem glioma**

Interestingly, the most frequent type of brainstem glioma in adults (representing 46% of the patients in this series) resembles the childhood diffuse gliomas of the pons in terms of clinical and radiological presentation but is radically different in course and survival. In both adults and children, the clinical picture is of a combination of cranial nerve and long tract signs. However, while the onset is rapid in children, the duration of symptoms is often long in adults. (69)

In both children and adults, MRI at presentation reveals a diffuse infiltration of the pons, often increasing the size of the brainstem considerably. There is high signal on T2-weighted and low signal on T1-weighted images, which usually do not show contrast enhancement (100% in adults at diagnosis). It is worth noting that preferential location in the pons is less striking in adults than in children.

When a biopsy is performed, which is far from routine practice in these diffuse intrinsic forms, a malignant glioma (grades III–IV) is found in many children, whereas a less aggressive histology is found the adults. (69)

- **Malignant brainstem gliomas**

The other common tumour type identified in adult is clearly different from those discussed above. It occurs later than the diffuse, intrinsic, low-grade type and affects mainly older adults (most of them in their sixth decade). The clinical picture is characterized by the rapid onset of cranial nerve palsies and long tract signs leading to an early alteration in performance status. MRI reveals a brainstem mass that enhances after gadolinium infusion, often in a ring-like fashion. Contrast enhancement is a pejorative factor (particularly when the area of enhancement surrounded a low-signal area suggestive of necrosis) in contrast with children, in whom the prognostic value of contrast enhancement remains controversial. Pathologically, these tumours correspond to high-grade gliomas (grades III–IV) and median survival time is short (11.2 months) despite treatment with radiotherapy and chemotherapy. Thus, the clinical–radiological pattern, pathology and course closely resemble the common malignant supratentorial gliomas in adults and we suggest that this group be designated 'malignant brainstem gliomas'. (69)

- **Focal tectal gliomas**

Focal tectal gliomas represent the third type of adult brainstem glioma and constitute a small subgroup (8%) that also exists in children. The clinical picture is dominated by hydrocephalus. (69)

- **Other types**

Other types of brainstem glioma can be observed in adults such as exophytic contrast-enhancing glioma arising from the floor of the fourth ventricle; this entity, which is associated with a good prognosis, is also well described in children (representing up to 10% of brainstem gliomas). A likely explanation for this discrepancy between the two age-groups is that most of the exophytic gliomas correspond to pilocytic astrocytoma, a very rare type of tumour in adults. (69)

The brainstem is the second most frequent location of brain tumours after the optic pathways in patients with NF1. In contrast with children, in whom the course is usually very long, the tumour behaviour in adults with NF1 was much more aggressive, but larger series will be necessary to draw any conclusion on this point. (69)

- **Complications**

Except for locoregional progression, two main complications are observed during the course of adult brainstem gliomas, namely hydrocephalus and leptomeningeal dissemination. Hydrocephalus is observed in 20% of cases. Whereas some pontine tumours may have an important mass effect on the fourth ventricle, hydrocephalus is always associated with mesencephalic involvement and blockage of the CSF at the level of the sylvian aqueduct. Leptomeningeal dissemination occurred in 13% of cases and is the cause of a quarter of the deaths. This complication has also been reported with a high frequency in children. Close proximity of the tumour and CSF pathways could explain such an increased trend for leptomeningeal dissemination, but this remains to be demonstrated. (69)

- **The role of biopsy**

Finally, this classification may help in the selection of patients for biopsy. In children, MRI has become the reference for the diagnosis of brainstem glioma and is used for the current classification of these tumours. MRI has replaced biopsy in the diagnosis of paediatric diffuse brainstem gliomas, for which most authors agree that anticancer treatments can be administered without pathological confirmation if the clinical course is rapid. However, we believe that biopsy is not useful in the diagnosis of intrinsic, diffuse, low-grade brainstem gliomas in adults when the clinical and radiological criteria described above are met. The issue is different in contrast-enhancing lesions because several reports have underlined the limits of MRI in differentiating tumours from infectious (e.g. tuberculomas) and inflammatory (sarcoidosis, Behcet's disease). (69)

---

- **Addendum**

- A new version of this PDF file (with a new case) is uploaded in my web site every week (every Saturday and remains available till Friday.)
  - To download the current version follow the link "<http://pdf.yassermetwally.com/case.pdf>".
  - You can also download the current version from my web site at "<http://yassermetwally.com>".
  - To download the software version of the publication (crow.exe) follow the link: <http://neurology.yassermetwally.com/crow.zip>
  - The case is also presented as a short case in PDF format, to download the short case follow the link: <http://pdf.yassermetwally.com/short.pdf>
  - At the end of each year, all the publications are compiled on a single CD-ROM, please contact the author to know more details.
  - Screen resolution is better set at 1024\*768 pixel screen area for optimum display.
  - For an archive of the previously reported cases go to [www.yassermetwally.net](http://www.yassermetwally.net), then under pages in the right panel, scroll down and click on the text entry "downloadable case records in PDF format"
  - Also to view a list of the previously published case records follow the following link (<http://wordpress.com/tag/case-record/>) or click on it if it appears as a link in your PDF reader
-

**References**

1. Abbott R (1993) Tumors of the medulla. *Neurosurg Clin N Am* 4:519–527
2. Abbott R, Shiminski-Maher T, Wisoff JH, Epstein FJ (1991) Intrinsic tumors of the medulla: surgical complications. *Pediatr Neurosurg* 17:239–244
3. Abbott R, Feldstein N, Wisoff JH, Epstein FJ (1992) Osteoplastic lami-notomy in children. *Pediatr Neurosurg* 18:153–156
4. Abbott R, Shiminski-Maher T, Epstein FJ (1996) Intrinsic tumors of the me-dulla: predicting outcome after surgery. *Pediatr Neurosurg* 25:41–44
5. Albright AL (1996) Brain stem gliomas. In: Youmans J (ed) *Neurological sur-gery*. Saunders, Philadelphia, pp 2603– 2611
6. Albright AL, Guthkelch AN, Packer RJ, Price RA, Rourke LB (1986) Prognostic factors in pediatric brain-stem gliomas. *J Neurosurg* 65:751–755
7. Albright AL, Packer RJ, Zimmerman R, Rorke LB, Boyett J, Hammond GD (1993) Magnetic resonance scans should replace biopsies for the diagno-sis of diffuse brain stem gliomas: a report from the Children’s Cancer Group. *Neurosurgery* 33:1026–1030
8. Allen J (1983) Brain stem glioma. *Neurol Neurosurg Update Series* 4:2–7
9. Allen JC, Siffert J (1996) Contemporary chemotherapy issues for children with brainstem gliomas. *Pediatr Neurosurg* 24:98–102
10. Alvisi C, Cerisoli M, Maccheroni ME (1985) Long-term results of surgically treated brainstem gliomas. *Acta Neu-rochir* 76:12–17
11. Ammirati M, Bernardo A, Musumeci A, Bricolo A (2002) Comparison of dif-ferent infratentorial-supracerebellar ap-proaches to the posterior and middle incisural space: a cadaveric study. *J Neurosurg* 97:922–928
12. Barkovich AJ, Krischer J, Kun LE, Packer R, Zimmermann RA, Freeman CR, Wara WM, Albright L, Allen JC, Hoffman HJ (1990) Brain stem glio-mas: a classification system based on magnetic resonance imaging. *Pediatr Neurosurg* 16:73–83
13. Behnke J, Christen HJ, Bruck W, Markakis E (1997) Intra-axial endo-phytic tumors in the pons and/or me-dulla oblongata. I. Symptoms, neuroradiological findings, and histo-pathology in 30 children. *Childs Nerv Syst* 13:122–134
14. Beltramello A, Lombardo MC, Masotto B, Bricolo A (2000) Imaging of brain stem tumors. *Oper Tech Neurosurg* 3:87–105
15. Berger MS, Edwards MS, LaMasters D, Davis RL, Wilson CB (1983) Pediatric brain stem tumors: radiographic, pathological, and clinical correlations. *Neurosurgery* 12:298–302
16. Blaney S, Berg SL, Pratt C, Weitman S, Sullivan J, Luchtman-Jones L, Bern-stein M (2001) A phase I study of irinotecan in pediatric patients: a Pedi-atric Oncology Group study. *Clin Can-cer Res* 7:32–37
17. Bowers DC, Georgiades C, Aronson LJ, Carson BS, Weingart JD, Wharam MD, Melhem ER, Burger PC, Cohen KJ (2000) Tectal gliomas: natural history of an indolent lesion in pediatric pa-tients. *Pediatr Neurosurg* 32:24–29
18. Bowers DC, Krause TP, Aronson LJ, Barzi A, Burger PC, Carson BS, Weingart JD, Wharam MD, Melhem ER, Cohen KJ (2001) Second surgery for recurrent pilocytic astrocytoma in children. *Pediatr Neurosurg* 34:229–234
19. Bricolo A (2000) Surgical management of intrinsic brain stem gliomas. *Oper Tech Neurosurg* 3:137–154
20. Broniscer A, Gajjar A, Bhargava R, Langston JW, Heideman R, Jones D, Kun LE, Taylor J (1997) Brain stem involvement in children with neurofi-bromatosis type 1: role of magnetic resonance imaging and spectroscopy in the distinction from diffuse pontine glioma. *Neurosurgery* 40:331–338
21. Broniscer A, Leite CC, Lanchote VL, Machado TM, Cristofani LM (2000) Radiation therapy and high-dose tam-oxifen in the treatment of patients with diffuse brainstem gliomas: results of a Brazilian cooperative study. *Brainstem Glioma Cooperative Group. J Clin On-col* 18:1246–1253
22. Carson BSS, Guarnieri M (2002) Local therapy for brain tumors. *Adv Clin Neurosci* 12:89–99
23. Choux M, Lena G, Do L (2000) Brainstem tumors. In: Choux M, Di Rocco C, Hockley A (eds) *Pediatric neurosurgery*. Churchill Livingstone, New York, pp 471–491

24. Constantini S, Epstein F (1996) Ultra-sonic dissection. In: Rengachary SS (ed) Neurosurgery. McGraw-Hill, New York, pp 2714–2718
25. Dechambre S, Duprez T, Lecouvet F, Raftopoulos C, Gosnard G (1999) Diffusion-weighted MRI postoperative assessment of an epidermoid tumour in the cerebellopontine angle. *Neuroradiology* 41:829–831
26. Deletis V, Sala F, Morota N (2000) Intraoperative neurophysiological monitoring and mapping during brain stem surgery: a modern approach. *Oper Tech Neurosurg* 3:109–113
27. Epstein F (1985) A staging system for brainstem gliomas. *Cancer* 56:1804–1806
28. Epstein F, McCleary EL (1986) Intrinsic brain-stem tumors of childhood: surgical indications. *J Neurosurg* 64:11–15
29. Epstein F, Wisoff J (1987) Intra-axial tumors of the cervicomedullary junction. *J Neurosurg* 67:483–487
30. Epstein F, Wisoff JH (1988) Intrinsic brainstem tumors in childhood: surgical indications. *J Neurooncol* 6:309–317
31. Epstein FJ, Farmer JP (1993) Brain-stem glioma growth patterns. *J Neurosurg* 78:408–412
32. Epstein FJ, Ozek M (1993) The plated bayonet: a new instrument to facilitate surgery for intra-axial neoplasms of the spinal cord and brain stem. Technical note. *J Neurosurg* 78:505–507
33. Fischbein NJ, Prados MD, Wara W, Russo C, Edwards MS, Barkovich AJ (1996) Radiologic classification of brain stem tumors: correlation of magnetic resonance imaging appearance with clinical outcome. *Pediatr Neurosurg* 24:9–23
34. Freeman CR, Bourgouin PM, Sanford RA, Cohen ME, Friedman HS, Kun LE (1996) Long term survivors of childhood brain stem gliomas treated with hyperfractionated radiotherapy. Clinical characteristics and treatment related toxicities. The Pediatric Oncology Group. *Cancer* 77:555–562
35. Freeman CR, Kepner J, Kun LE, Sanford RA, Kadota R, Mandell L, Friedman H (2000) A detrimental effect of a combined chemotherapy-radiotherapy approach in children with diffuse intrinsic brain stem gliomas? *Int J Radiat Oncol Biol Phys* 47:561–564
36. Gilday DL, Ash J (1975) Accuracy of brain scanning in pediatric cranio-cerebral neoplasms. *Radiology* 117:93–97
37. Gnanalingham KK, Lafuente J, Thompson D, Harkness W, Hayward R (2002) Surgical procedures for posterior fossa tumors in children: does craniotomy lead to fewer complications than craniectomy? *J Neurosurg* 97:821–826
38. Hoffman HJ, Becker L, Craven MA (1980) A clinically and pathologically distinct group of benign brain stem gliomas. *Neurosurgery* 7:243–248
39. Jallo G, Kothbauer K, Epstein F (2000) Surgical management of cervico-medullary and dorsally exophytic brain stem tumors. *Oper Tech Neurosurg* 3:131–136
40. Jallo GI (2001) CUSA excel ultrasonic aspiration system. *Neurosurgery* 48:695–697
41. Jallo GI, Kothbauer KF, Epstein FJ (2002) Contact laser microsurgery. *Childs Nerv Syst* 18:333–336
42. Kaplan AM, Albright AL, Zimmerman RA, Rorke LB, Li H, Boyett JM, Finlay JL, Wara WM, Packer RJ (1996) Brainstem gliomas in children. A Children's Cancer Group review of 119 cases. *Pediatr Neurosurg* 24:185–192
43. Kedar A, Maria BL, Graham-Pole J, Ringdahl DM, Quisling RG, Mickle JP, Mendenhall NP, Marcus RB Jr, Gross S (1994) High-dose chemotherapy with marrow reinfusion and hyperfractionated irradiation for children with high-risk brain tumors. *Med Pediatr Oncol* 23:428–436
44. Khatib ZA, Heideman RL, Kovnar EH, Langston JA, Sanford RA, Douglas EC, Ochs J, Jenkins JJ, Fairclough DL, Greenwald C et al (1994) Predominance of pilocytic histology in dorsally exophytic brain stem tumors. *Pediatr Neurosurg* 20:2–10
45. Kurpad SN, Cohen AR (1999) Posterior fossa craniotomy: an alternative to craniectomy. *Pediatr Neurosurg* 31:54–57
46. Littman P, Jarrett P, Bilaniuk LT, Rorke LB, Zimmerman RA, Bruce DA, Carabell SC, Schut L (1980) Pediatric brain stem gliomas. *Cancer* 45:2787–2792
47. Lonser RR, Walbridge S, Garmestani K, Butman JA, Walters HA, Vortmeyer AO, Morrison PF, Brechbiel MW, Oldfield EH (2002) Successful and safe perfusion of the primate brainstem: in vivo magnetic resonance imaging of macromolecular distribution during infusion. *J Neurosurg* 97:905–913



48. Matson D (1969) Tumors of the posterior fossa. In: Thomas C (ed) Neuro-surgery of infancy and childhood. Thomas, Springfield, pp 469–477
49. Milstein JM, Geyer JR, Berger MS, Bleyer WA (1989) Favorable prognosis for brainstem gliomas in neurofibromatosis. *J Neurooncol* 7:367–371
50. Morota N, Deletis V, Epstein FJ, Kofler M, Abbott R, Lee M, Ruskin K (1995) Brain stem mapping: neurophysiological localization of motor nuclei on the floor of the fourth ventricle. *Neurosurgery* 37:922–930
51. Murakami N, Matsushima T, Kuba H, Ikezaki K, Morioka T, Mihara F, Inamura T, Fukui M (1999) Combining steady-state constructive interference and diffusion-weighted magnetic resonance imaging in the surgical treatment of epidermoid tumors. *Neurosurg Rev* 22:159–162
52. Pollack IF, Hoffman HJ, Humphreys RP, Becker L (1993) The long-term outcome after surgical treatment of dorsally exophytic brain-stem gliomas. *J Neurosurg* 78:859–863
53. Pollack IF, Polinko P, Albright AL, Towbin R, Fitz C (1995) Mutism and pseudobulbar symptoms after resection of posterior fossa tumors in children: incidence and pathophysiology. *Neuro-surgery* 37:885–893
54. Raffel C, McComb JG, Bodner S, Gilles FE (1989) Benign brain stem lesions in pediatric patients with neurofibromatosis: case reports. *Neurosurgery* 25:959–964
55. Rhoton AL (2000) Cerebellum and fourth ventricle. *Neurosurgery (Supplement)* 47:S7–S27
56. Robertson PL, Allen JC, Abbott IR, Miller DC, Fidel J, Epstein FJ (1994) Cervicomedullary tumors in children: a distinct subset of brainstem gliomas. *Neurology* 44:1798–1803
57. Rose E (1998) Aesthetic facial restoration. Lippincott-Raven, New York
58. Sandberg DI, Edgar MA, Souweidane MM (2002) Convection-enhanced delivery into the rat brainstem. *J Neuro-surg* 96:885–891
59. Stein B (1971) The infratentorial supracerebellar approach to pineal lesions. *J Neurosurg* 35:197–202
60. Steinbok P, Cochrane DD, Perrin R, Price A (2003) Mutism after posterior fossa tumour resection in children: incomplete recovery on long-term follow-up. *Pediatr Neurosurg* 39:179–183
61. Storm PB, Clatterbuck RE, Liu YJ, Johnson RM, Gillis EM, Guarnieri M, Carson BS (2003) A surgical technique for safely placing a drug delivery catheter into the pons of primates: preliminary results of carboplatin infusion. *Neurosurgery* 52:1169–1177
62. Stroink AR, Hoffman HJ, Hendrick EB, Humphreys RP, Davidson G (1987) Transependymal benign dorsally exophytic brain stem gliomas in childhood: diagnosis and treatment recommendations. *Neurosurgery* 20:439–444
63. Walker DA, Punt JA, Sokal M (1999) Clinical management of brain stem glioma. *Arch Dis Child* 80:558–564
64. Walter AW, Gajjar A, Ochs JS, Langston JW, Sanford RA, Kun LE, Heide-man R (1998) Carboplatin and etoposide with hyperfractionated radio-therapy in children with newly diagnosed diffuse pontine gliomas: a phase I/II study. *Med Pediatr Oncol* 30:28–33
65. Wang G, Zhang J, Sun M, Wang C (2001) Surgical management of brain-stem mass lesions: respiratory insufficiency occurrence and recovery. *Neurosurg Q* 11:302–313
66. Weiner HL, Freed D, Woo HH, Rezai AR, Kim R, Epstein FJ (1997) Intra-axial tumors of the cervicomedullary junction: surgical results and long-term outcome. *Pediatr Neurosurg* 27:12–18
67. Wisoff JH, Epstein FJ (1984) Pseudo-bulbar palsy after posterior fossa operation in children. *Neurosurgery* 15:707–709
68. Zagzag D, Miller DC, Knopp E, Farmer JP, Lee M, Biriya S, Pellicer A, Epstein FJ, Allen JC (2000) Primitive neuroectodermal tumors of the brainstem: Investigation of seven cases. *Pediatrics* 106:1045–1053
69. Metwally, MYM: Textbook of neuroimaging, A CD-ROM publication, (Metwally, MYM editor) WEB-CD agency for electronic publication, version 11.1a. January 2010
70. Metwally, MYM (2001): Brain stem glioma, A clinico-radiological study: A classification system with prognostic significance is suggested. *Ain Shams medical journal*, VOL. 51, NO. 10,11,12, pp 1085-1115 [\[Click to download in PDF format\]](#)