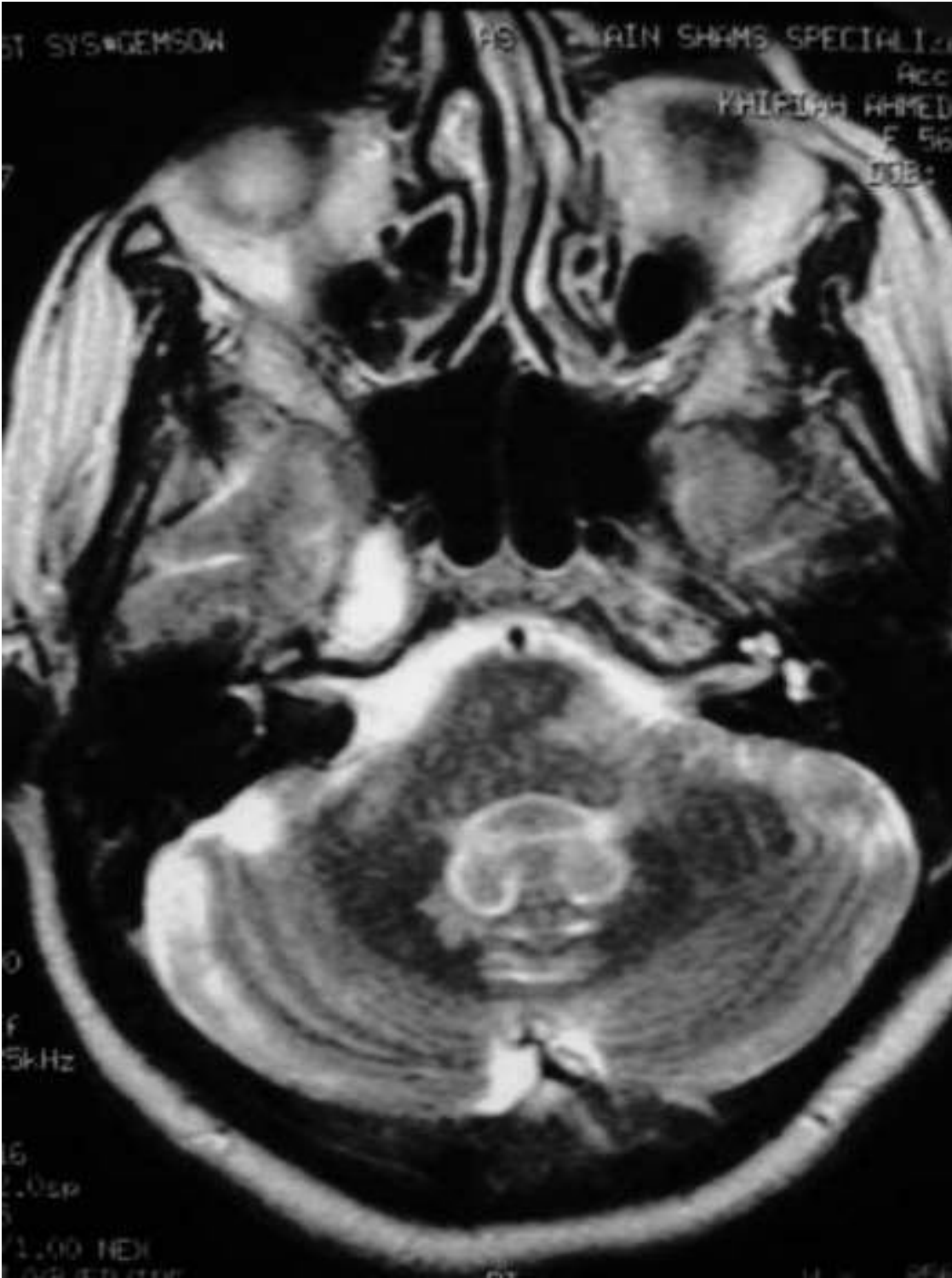

Short case

Short case publication... Version 3.5 | Edited by professor Yasser Metwally | November 2009



Short case

Edited by
Professor Yasser Metwally
Professor of neurology
Ain Shams university school of medicine
Cairo, Egypt

Visit my web site at:
<http://yassermetwally.com>

A 48-year-old female patient was admitted to our hospital due to sudden gait disturbance.

DIAGNOSIS: STROKE MIMICKING PARANEOPLASTIC LEUKOENCEPHALOPATHY AS AN INITIAL MANIFESTATIONS OF DIFFUSE LARGE B-CELL LYMPHOMA

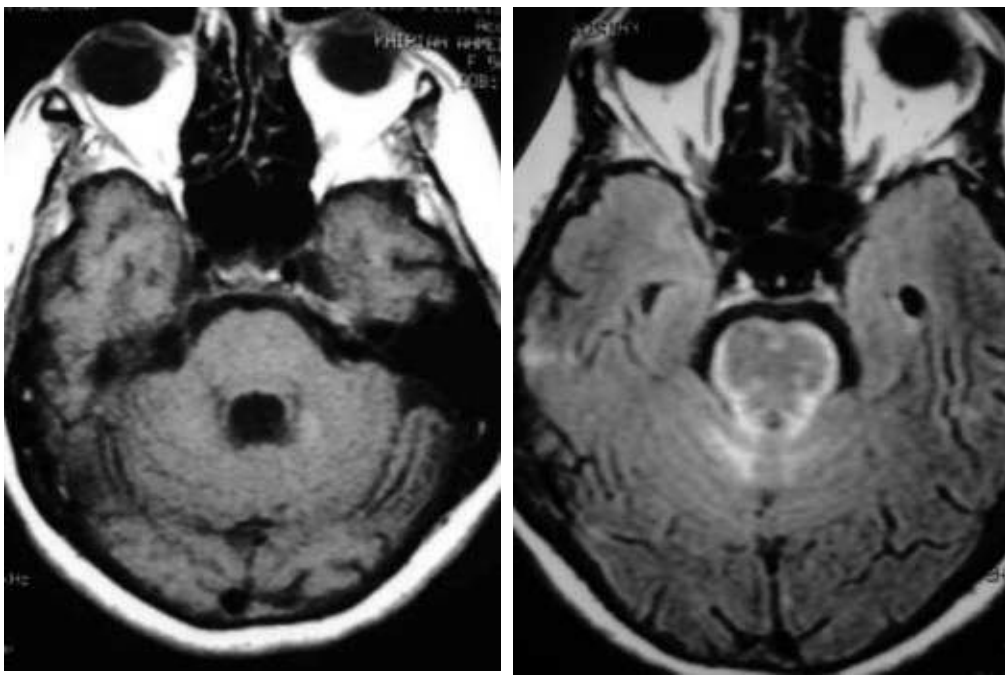


Figure 1. Precontrast (A) and postcontrast (B) MRI T1 images showing scattered cerebellar, temporal lobes and brain stem hypointense zones, with mild enlargement of the temporal horns bilaterally. Also noticed meningeal enhancement completely ensheathing the pons.

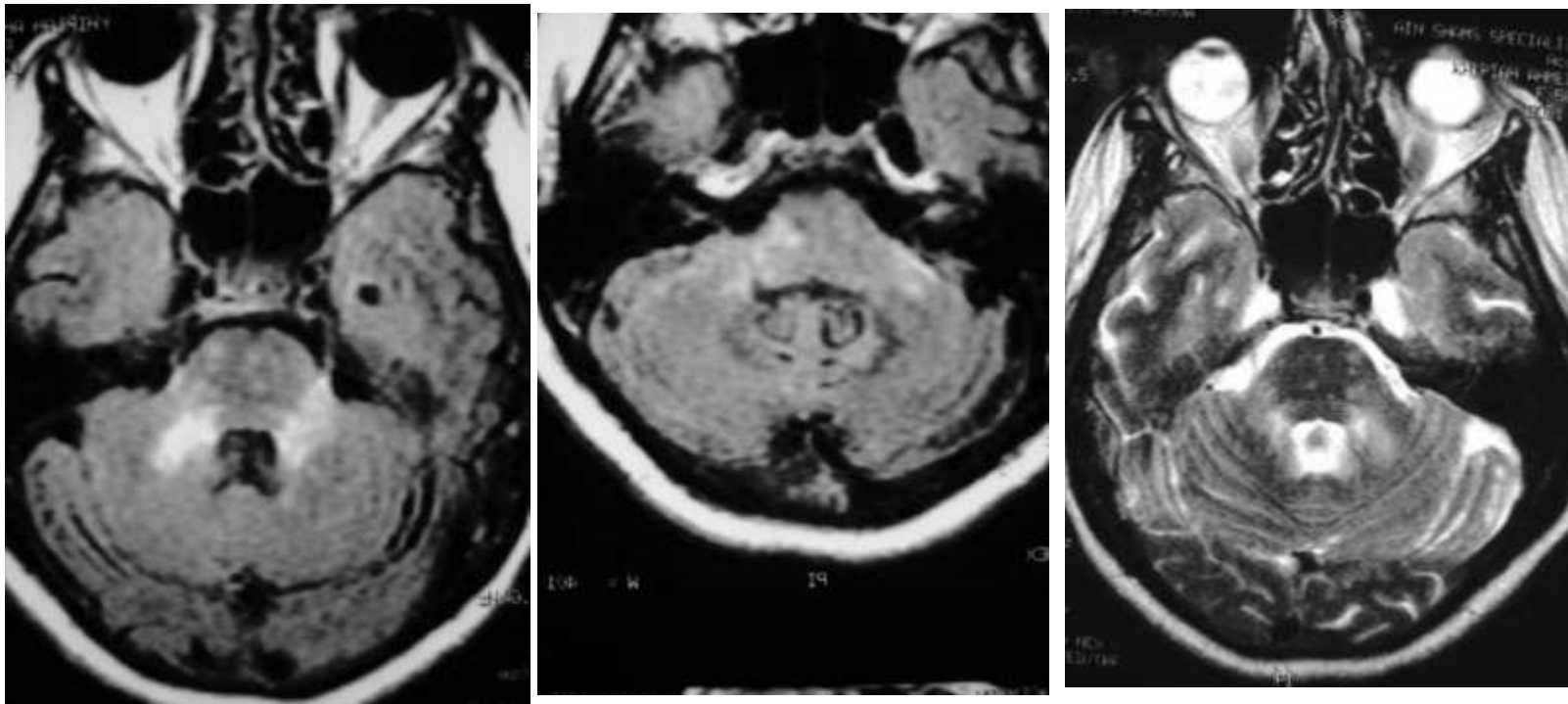


Figure 2. MRI FLAIR (A,B) and MRI T2 images showing scattered hyperintense zones around the 4th ventricle and within the pons. The hyperintense zones have no mass effect.

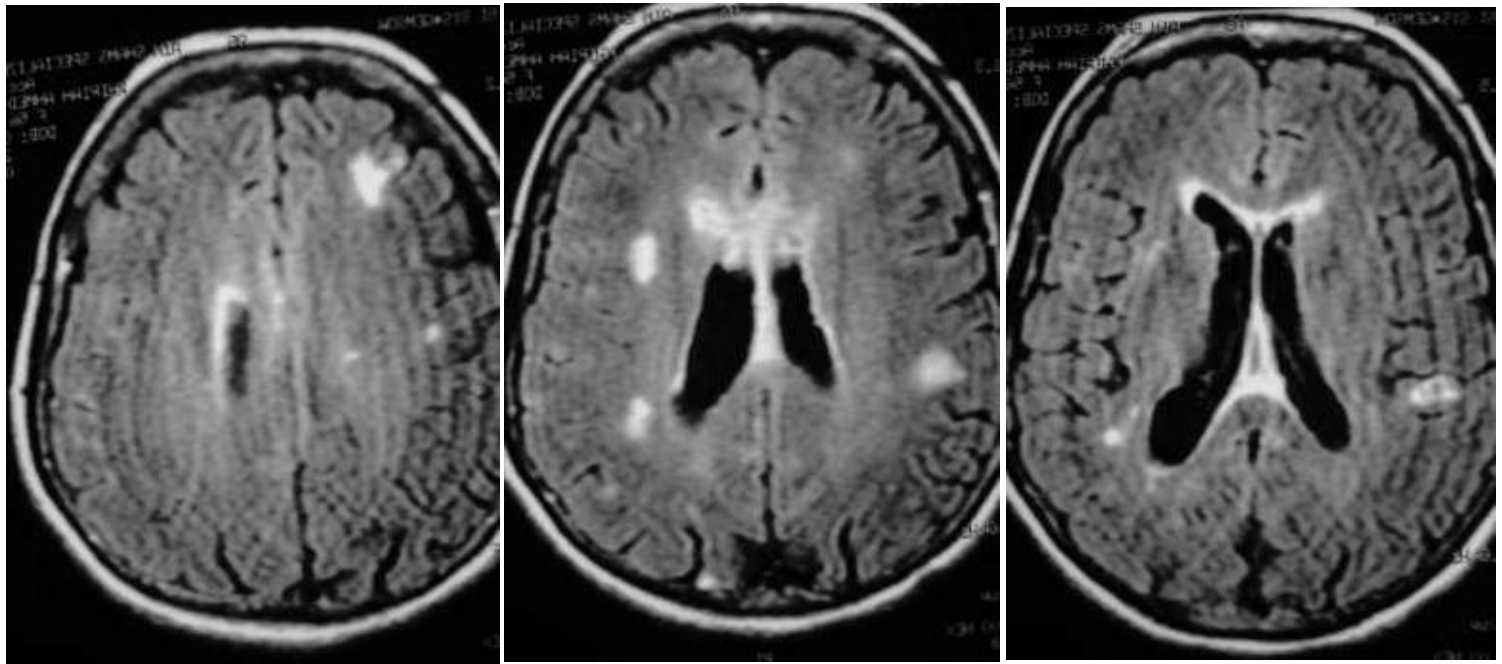


Figure 3. MRI FLAIR images showing bilateral hyperintense zones scattered in the cerebral white matter and the immediate periventricular area, especially involving the genu of the corpus callosum. The hyperintense lesions apparently have no mass effect. Notice the moderate hydrocephalic changes.

References

1. Metwally, MYM: Textbook of neurimaging, A CD-ROM publication, (Metwally, MYM editor) WEB-CD agency for electronic publishing, version 10.4a October 2009

Addendum

- ◆ A new version of short case is uploaded in my web site every week (every Saturday and remains available till Friday.)
- ◆ To download the current version follow the link "<http://pdf.yassermetwally.com/short.pdf>".
- ◆ You can download the long case version of this short case during the same week from: <http://pdf.yassermetwally.com/case.pdf> or visit web site: <http://pdf.yassermetwally.com>
- ◆ To download the software version of the publication (crow.exe) follow the link: <http://neurology.yassermetwally.com/crow.zip>
- ◆ At the end of each year, all the publications are compiled on a single CD-ROM, please contact the author to know more details.
- ◆ Screen resolution is better set at 1024*768 pixel screen area for optimum display
- ◆ For an archive of the previously reported cases go to www.yassermetwally.net, then under pages in the right panel, scroll down and click on the text entry "downloadable short cases in PDF format"
- ◆ Also to view a list of the previously published case records follow the following link (<http://wordpress.com/tag/case-record/>) or click on it if it appears as a link in your PDF reader