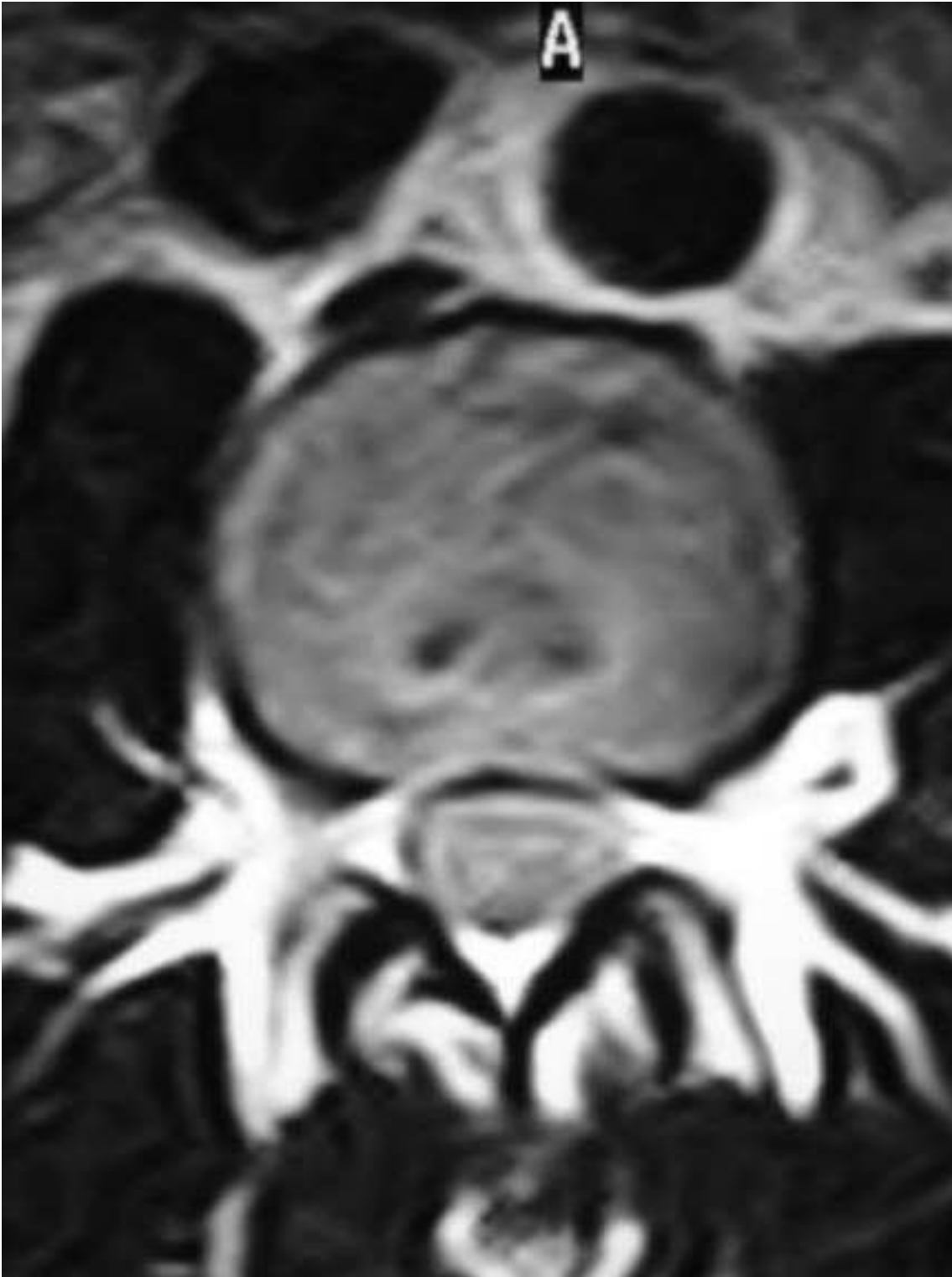

# Short case

Short case publication... Version 2.18 | Edited by professor Yasser Metwally | May 2009



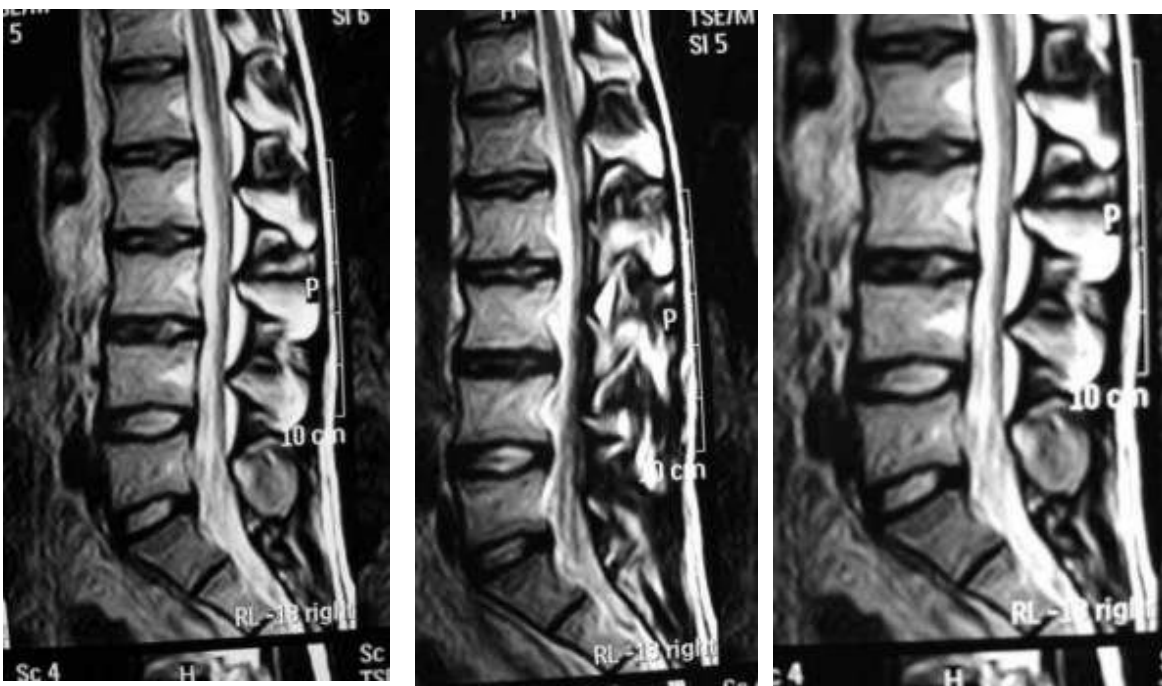
## Short case

Edited by  
Professor Yasser Metwally  
Professor of neurology  
Ain Shams university school of medicine  
Cairo, Egypt

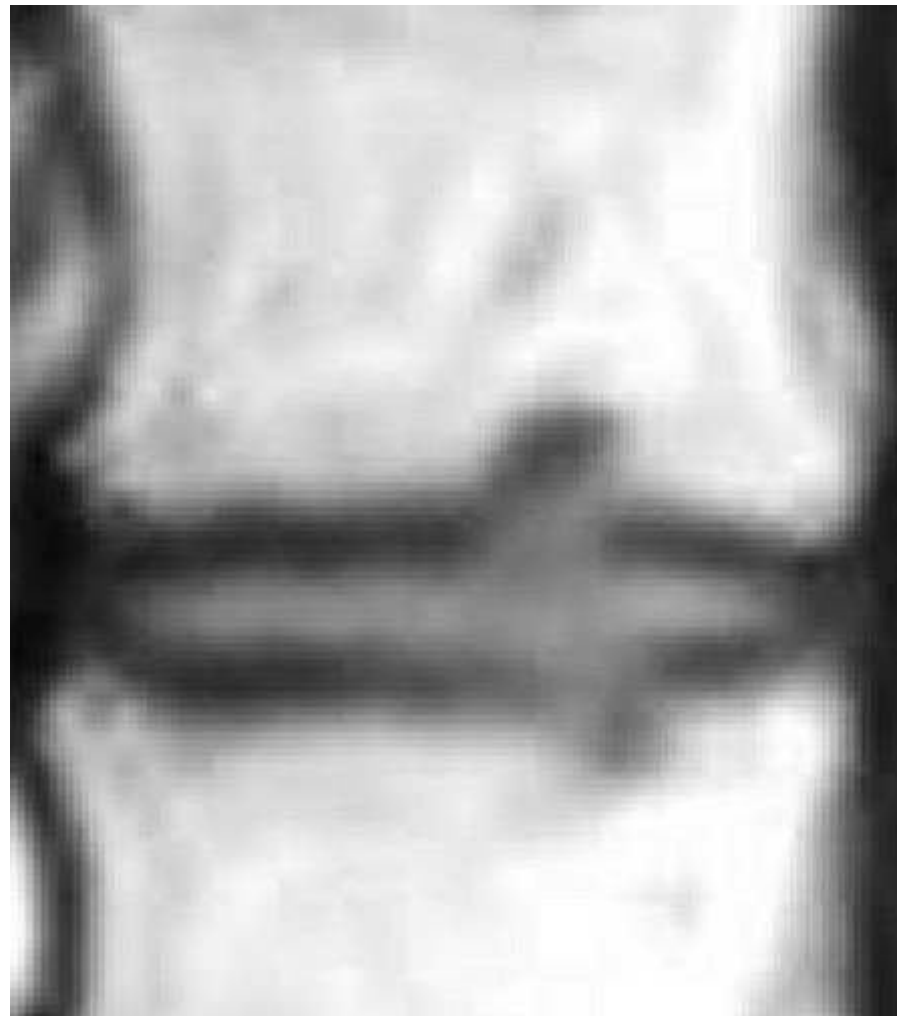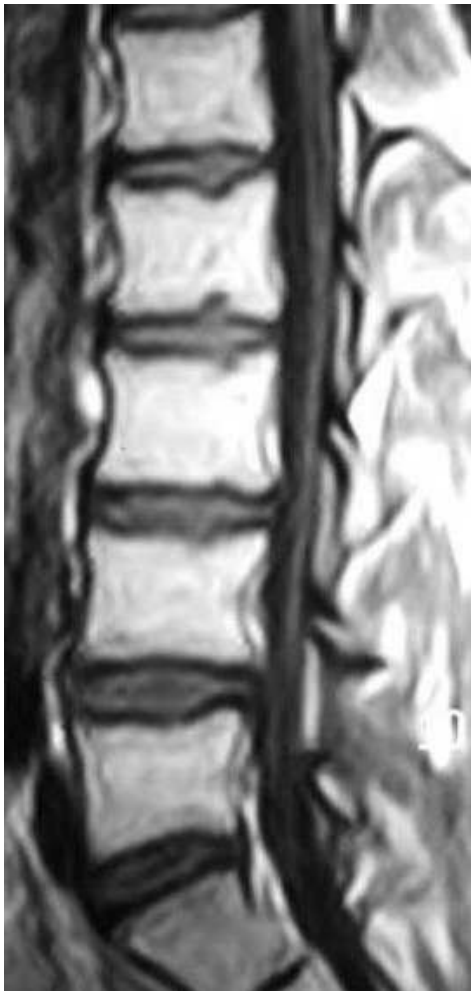Visit my web site at:  
<http://yassermetwally.com>

A 66 years old male patient presented clinically with non specific lumbar spine pain.

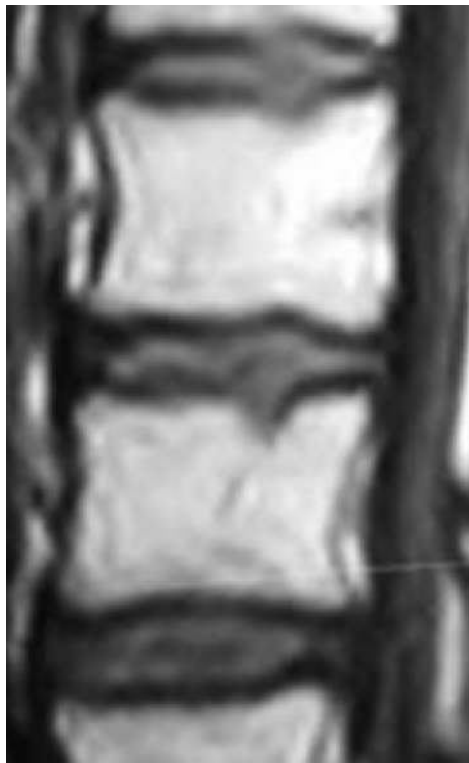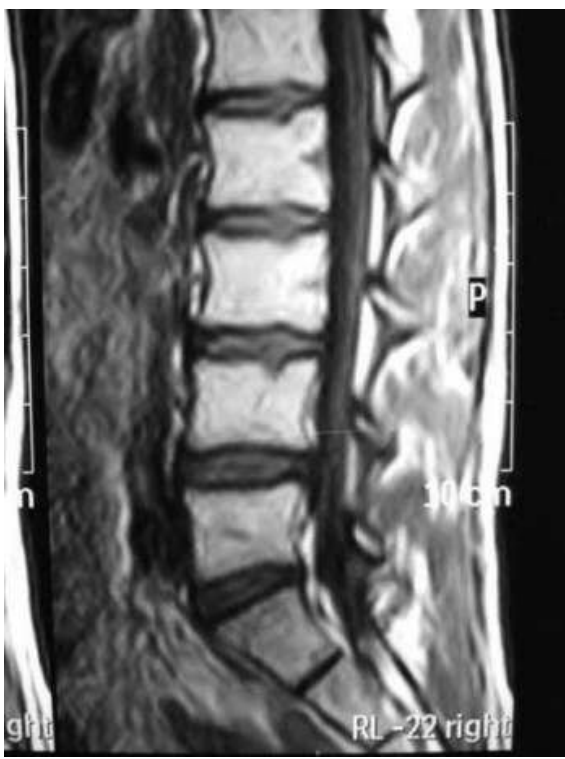**DIAGNOSIS:**LUMBAR SPONDYLOSIS.



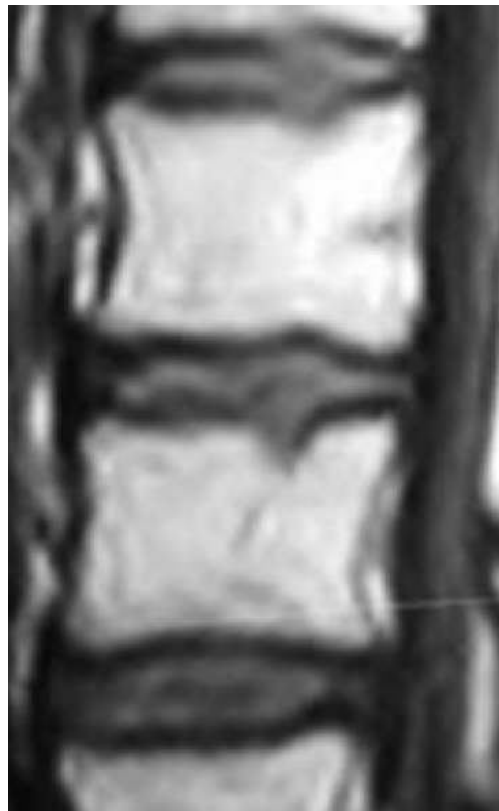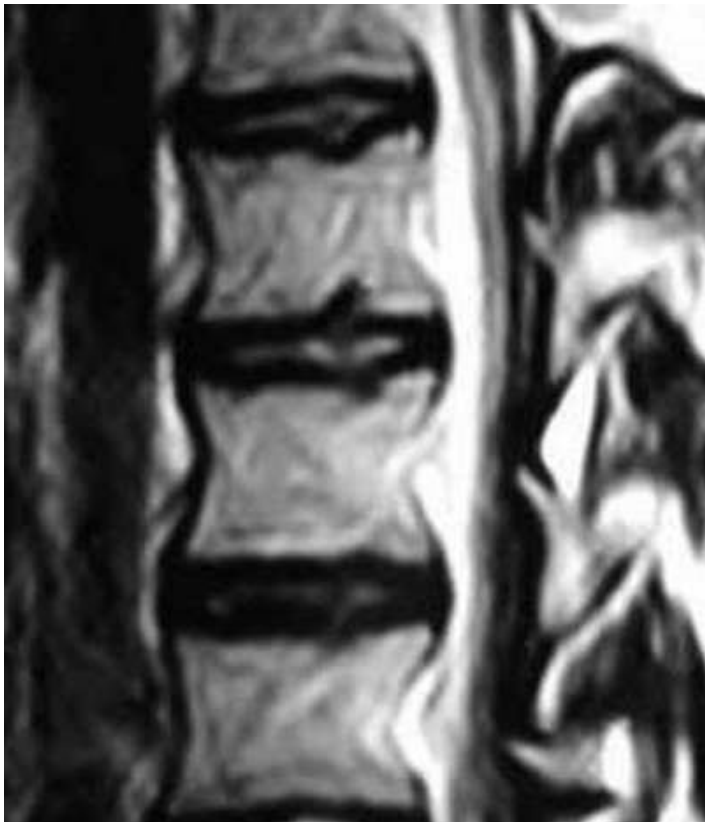**Figure 1.** MRI T2 images of the lumbar spine (Sagittal view) showing reduction of the T2 signal of the upper lumbar discs denoting disc degeneration. Annular bulging is seen at L3-L4 and L4-L5. Notice the intranuclear cleft that transverse the equator of the disc between L4-L5. Also notice the vertical disc herniation (Schmorl's nodule) in the upper lumbar vertebrae.



**Figure 2.** MRI T1 images showing vertical disc herniation (Schmorl's nodule) in the upper lumbar vertebrae.



**Figure 3. MRI T1 images showing vertical disc herniation (Schmorl's nodule) in the upper lumbar vertebrae**



**Figure 4. MRI T2 (A) and T1 (B) images showing vertical disc herniation (Schmorl's nodule) in the upper lumbar vertebrae**

## References

1. Metwally, MYM: Textbook of neurimaging, A CD-ROM publication, (Metwally, MYM editor) WEB-CD agency for electronic publishing, version 10.2a April 2009

## **Addendum**

- ◆ A new version of short case is uploaded in my web site every week (every Saturday and remains available till Friday.)
- ◆ To download the current version follow the link "<http://pdf.yassermetwally.com/short.pdf>".
- ◆ You can download the long case version of this short case during the same week from: <http://pdf.yassermetwally.com/case.pdf> or visit web site: <http://pdf.yassermetwally.com>
- ◆ To download the software version of the publication (crow.exe) follow the link: <http://neurology.yassermetwally.com/crow.zip>
- ◆ At the end of each year, all the publications are compiled on a single CD-ROM, please contact the author to know more details.
- ◆ Screen resolution is better set at 1024\*768 pixel screen area for optimum display
- ◆ For an archive of the previously reported cases go to [www.yassermetwally.net](http://www.yassermetwally.net), then under pages in the right panel, scroll down and click on the text entry "downloadable short cases in PDF format"
- ◆ Also to view a list of the previously published case records follow the following link (<http://wordpress.com/tag/case-record/>) or click on it if it appears as a link in your PDF reader