

# Online brainmapping

Version 14

A Monthly Publication presented by Professor Yasser Metwally

June 2009

## DEFINITION OF HEPATIC ENCEPHALOPATHY

Hepatic encephalopathy is a syndrome observed in patients with cirrhosis of the liver. It is characterized by personality changes, intellectual impairment, and a depressed level of consciousness. An important prerequisite for the syndrome is diversion of portal blood into the systemic circulation through portosystemic collateral vessels. Indeed, hepatic encephalopathy may develop in patients without cirrhosis who have undergone portocaval shunt surgery. The development of hepatic encephalopathy is explained, to some extent, by the effect of neurotoxic substances, which occurs in the setting of cirrhosis and portal hypertension.

Subtle signs of hepatic encephalopathy are observed in nearly 70% of patients with cirrhosis. Symptoms may be debilitating in a significant number of patients and are observed in 24-53% of patients who undergo portosystemic shunt surgery. Approximately 30% of patients dying of end-stage liver disease experience significant encephalopathy, approaching coma.

Hepatic encephalopathy accompanied by severe dysfunction of hepatic synthetic activity also is the hallmark of fulminant hepatic failure (FHF). Symptoms of encephalopathy in FHF are graded using the same scale employed to assess encephalopathy symptoms in cirrhosis. However, the pathogenesis of the encephalopathy in FHF differs from that of cirrhosis. In FHF, altered mental function is attributed to increased permeability of the blood-brain barrier and to impaired osmoregulation within the brain. The resulting brain cell swelling and brain edema are potentially fatal. In contrast, brain edema rarely is reported in patients with cirrhosis.

## TRIPHASIC WAVE CHARACTERISTICS

An elevated blood ammonia level is the classic laboratory abnormality reported in patients with hepatic encephalopathy. This finding may aid in correctly diagnosing patients with cirrhosis who present with altered mental status. However, serial ammonia measurements are inferior to clinical assessment in gauging improvement or deterioration in a patient under therapy for hepatic encephalopathy. Checking the ammonia level in a patient with cirrhosis who does not have hepatic encephalopathy has no utility. Only arterial or "free venous" blood specimens must be assayed when checking the ammonia level. Blood drawn from an extremity to which a tourniquet has been applied may provide a falsely elevated ammonia level when analyzed.

Classic EEG changes associated with hepatic encephalopathy are high-amplitude low-frequency waves and triphasic waves. However, these findings are not specific for hepatic encephalopathy. When seizure activity must be ruled out, an EEG may be helpful in the initial workup of a patient with cirrhosis and altered mental status. Visual evoked responses also demonstrate classic patterns associated with hepatic encephalopathy. However, such testing is not performed in common clinical use.

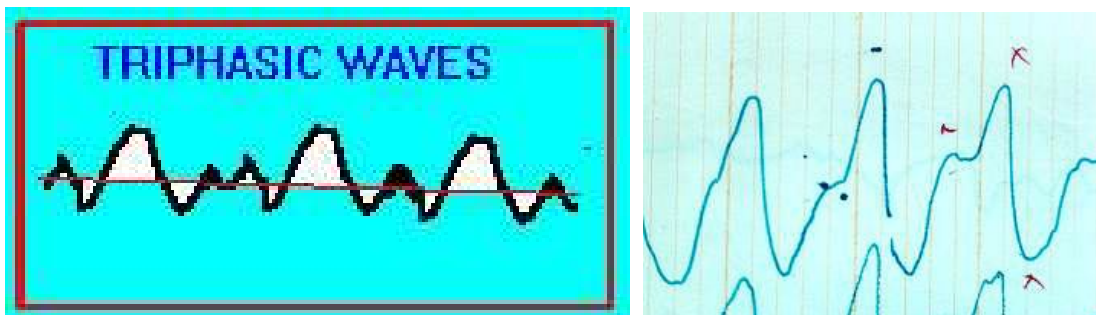


Figure 1. Triphasic waves

Triphasic waves (TWs) are a distinctive but nonspecific electroencephalographic (EEG) pattern originally described in a stuporous patient in 1950 by Foley as "blunted spike and wave." In 1955, Bickford and Butt coined the term "triphasic wave." Since their findings were limited to patients with hepatic failure, triphasic wave encephalopathy (TWE) became synonymous with hepatic encephalopathy. More recently, TWE has been associated with a wide range of toxic, metabolic, and structural abnormalities.

TWs are large-amplitude, generalized waves of 1.5-3.0 Hz. They are bilaterally synchronous and bifrontally predominant periodic waves with a characteristic morphology. Classic TWs have an initial small-amplitude, sharp-negative component followed by a large-amplitude, sharp-positive wave; they end with a slow negative wave.

The 3 most common causes of TWE are hepatic encephalopathy, renal failure, and anoxic injury. Other causes of TWs include the following:

1. Hepatic failure
2. Metabolic abnormalities such as hypernatremia, hyponatremia, hypercalcemia, and hypoglycemia
3. Thyroid disease - Hyperthyroidism or hypothyroidism
4. Encephalitis
5. Stroke
6. Creutzfeldt-Jakob disease (CJD)
7. Alzheimer disease
8. Postictal state
9. Serotonin syndrome
10. Cerebral abscess
11. Metrizamide poisoning
12. Naproxen overdose
13. Lithium toxicity
14. Head trauma
15. Cerebral lipidoses
16. Subdural hematoma
17. Carcinomatous meningitis
18. Tumors
19. Maple syrup urine disease

## PATHOPHYSIOLOGY OF TRIPHASIC WAVES

Regardless of the underlying etiology, TWs invariably are associated with an impaired consciousness that may range from mild confusion to deep coma. The background may be slower in hepatic failure than in other conditions. Patients with metabolic abnormalities as a cause for TWE are more likely to be in coma than those with another etiology of TWE.

Early theories suggested that moving cortical positivity due to cortical irritation produced TWE. The cause now is believed to be a dysfunction of the thalamocortical relay neurons due to structural or metabolic disruption. Abnormalities in glutamate metabolism may be one of the mechanisms of TWE. Metabolic or structural abnormalities at the thalamocortical level, particularly dysfunction in the thalamocortical relay neurons, are hypothesized to be responsible for the EEG and clinical findings associated with TWE.

## References

1. Bahamon-Dussan JE, Celesia GG, Grigg-Damberger MM: Prognostic significance of EEG triphasic waves in patients with altered state of consciousness. *J Clin Neurophysiol* 1989 Oct; 6(4): 313-9.
2. Bickford RG, Butt HR: coma: The electroencephalographic pattern. *J Clin Invest* 1955; 34: 790-99.
3. Blatt I, Brenner RP: Triphasic waves in a psychiatric population: a retrospective study. *J Clin Neurophysiol* 1996 Jul; 13(4): 324-9.
4. Bortone E, Bettoni L, Buzio S, et al: Triphasic waves associated with acute naproxen overdose: a case report. *Clin Electroencephalogr* 1998 Jul; 29(3): 142-5.
5. Dike GL: Triphasic waves in serotonin syndrome [letter]. *J Neurol Neurosurg Psychiatry* 1997 Feb; 62(2): 200.
6. Fisch BJ, Klass DW: The diagnostic specificity of triphasic wave patterns. *Electroencephalogr Clin Neurophysiol* 1988 Jul; 70(1): 1-8.
7. Foley JM, Watson CW, Adams RD: Significance of the electroencephalographic changes in hepatic coma. *Trans Am Neurol Assoc* 1950; 75: 161-165.
8. Karnaze DS, Bickford RG: Triphasic waves: a reassessment of their significance. *Electroencephalogr Clin Neurophysiol* 1984 Mar; 57(3): 193-8.
9. Korein J, Sansaricq C, Kalmijn M, et al: Maple syrup urine disease: clinical, EEG, and plasma amino acid correlations with a theoretical mechanism of acute neurotoxicity. *Int J Neurosci* 1994 Nov; 79(1-2): 21-45.
10. Martinez-Lage JF, Sola J, Poza M, Esteban JA: Pediatric Creutzfeldt-Jakob disease: probable transmission by a dural graft. *Childs Nerv Syst* 1993 Jul; 9(4): 239-42.
11. Ogunyemi A: Triphasic waves during post-ictal stupor. *Can J Neurol Sci* 1996 Aug; 23(3): 208-12.
12. River Y, Zelig O: Triphasic waves in myxedema coma. *Clin Electroencephalogr* 1993 Jul; 24(3): 146-50.
13. Sundaram MB, Blume WT: Triphasic waves: clinical correlates and morphology. *Can J Neurol Sci* 1987 May; 14(2): 136-40.
14. Townsend JB, Drury I: Triphasic waves in coma from brainstem infarction. *Eur Neurol* 1991; 31(1): 47-9.
15. Yamashita S, Morinaga T, Ohgo S, et al: Prognostic value of electroencephalogram (EEG) in anoxic encephalopathy after cardiopulmonary resuscitation: relationship among anoxic period, EEG grading and outcome. *Intern Med* 1995 Feb; 34(2): 71-6.
16. Young GB, Bolton CF, Archibald YM, et al: The electroencephalogram in sepsis-associated encephalopathy. *J Clin Neurophysiol* 1992 Jan; 9(1): 145-52.

The author,  
Professor Yasser Metwally  
Professor of clinical neurology, Ain Shams university, Cairo, Egypt.  
[www.yassermetwally.com](http://www.yassermetwally.com)

- ◆ A new version of this publication is uploaded in my web site every month
  - ◆ Follow the following link to download the current version:  
<http://brainmapping.yassermetwally.com/map.pdf>

© Yasser Metwally, all rights reserved